



Volume 7, No. 1 Spring/printemps 2014

# CJRDP

# JCDRP

Fixed Prosthodontics/Prosthodontie fixe

Sleep Dentistry/Dentisterie du sommeil

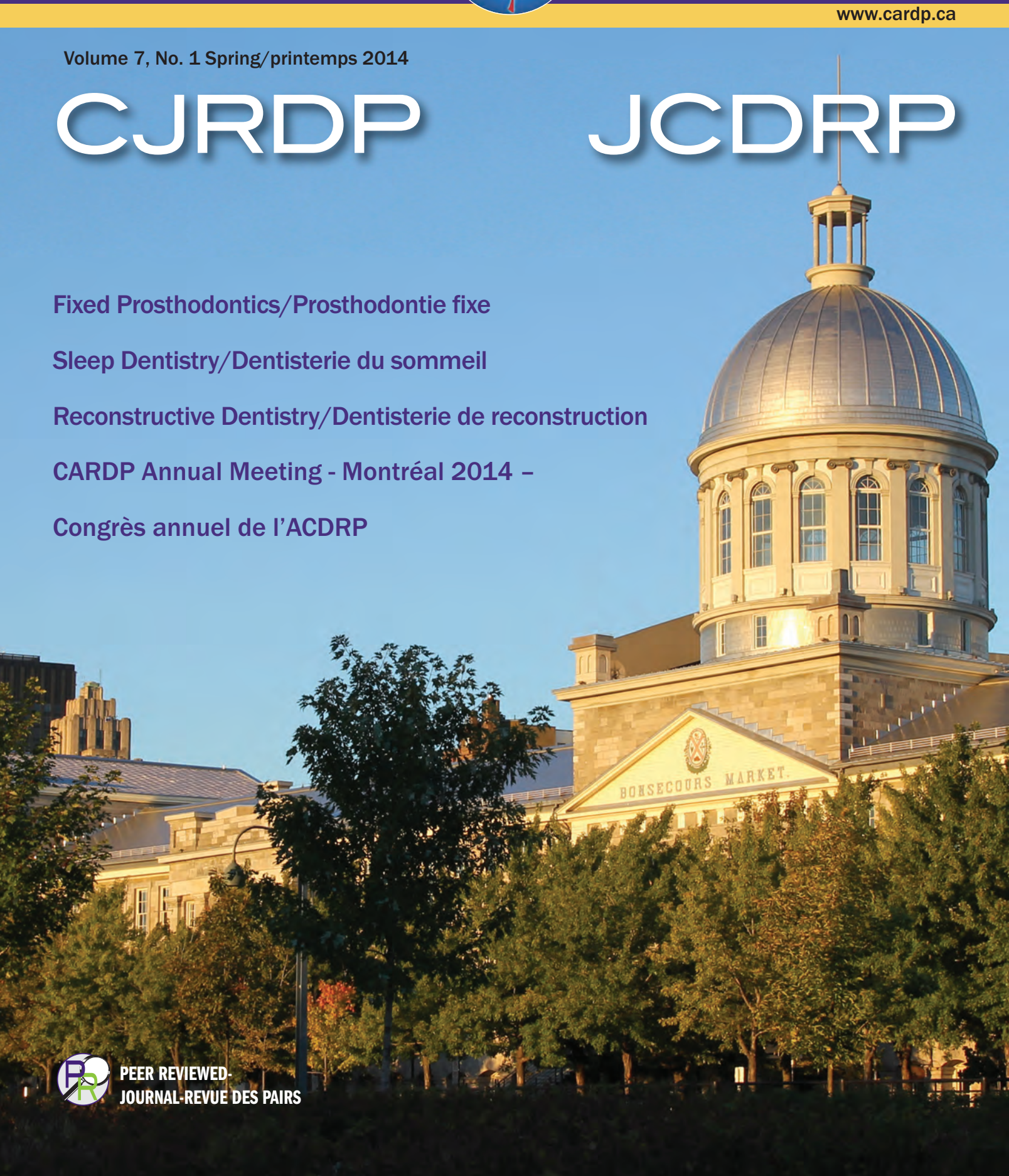
Reconstructive Dentistry/Dentisterie de reconstruction


CARDP Annual Meeting - Montréal 2014 -

Congrès annuel de l'ACDRP



PEER REVIEWED  
JOURNAL-REVUE DES PAIRS





# eCEMENT™

THE ONLY KIT you'll need for all your lithium disilicate (e.g. IPS e.max®) restorations!

- |   |  |
|---|--|
| <ul style="list-style-type: none"> <li>✓ Veneers</li> <li>✓ Inlays</li> <li>✓ Onlays</li> <li>✓ Crowns</li> </ul> | <ul style="list-style-type: none"> <li>✓ Three-unit bridges</li> <li>✓ All common CAD/CAM blocks made of Lithium Disilicate</li> </ul> |
|---|--|



### Universal, versatile

- Compatible with veneers, crowns and bridges including all common CAD/CAM blocks made of lithium disilicate

### Easy removal of excess cement

- Ease of use and great handling

### Low film thickness

- Ensures the restoration will be completely seated

### Multiple shades of light-cured cement

- No shade shift allowing for a natural looking restoration and providing superior esthetic qualities

### Exceptional physical properties

- Assures restoration will stand up to the daily stress and pressures

### Radiopaque

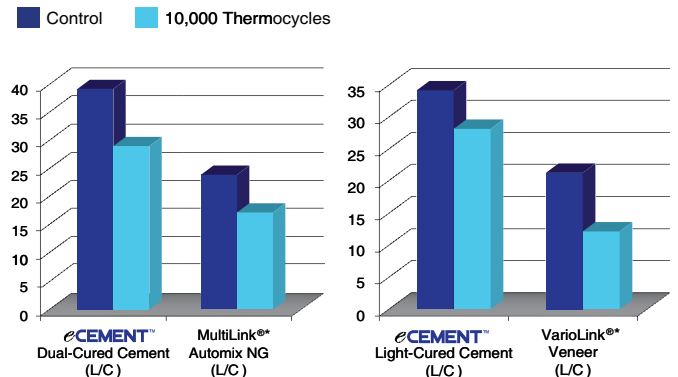
- Allows for better visual assessment on radiographs

### Complete kit with all components needed to successfully cement lithium disilicate restorations

- Simple and convenient, reduce inventory of multiple bonding agents and cements.

### Shear Bond Strength of Ceramic Bonding to IPS e.max® (MPa)

Shear bond strength generated using Ultradent methods on dentin.



BISCO DENTAL PRODUCTS CANADA INC.

Head Office: 800.667.8811

Français: 800.211.1200

CJRDP Editorial Board/Le comité de rédaction JCDRP



EDITOR-IN-CHIEF/  
RÉDACTEUR EN CHEF



Dr. Hubert Gaucher  
Québec City, Québec  
hgaucher@sympatico.ca

ASSOCIATE EDITORS/  
RÉDACTEURS ASSOCIÉS



Dr. Emmanuel J. Rajczak  
Hamilton, Ontario  
ejrajczak@cogeco.ca



Dr. Maureen Andrea  
Chester, Nova Scotia  
chesterclinicdental@ns.aliantzinc.ca



Dr. Dennis Nimchuk  
Vancouver, British Columbia  
drm@dentalreconstructions.com

SECTION EDITORS/RÉDACTEURS DE SECTIONS



**Occlusion and Temporo-  
Mandibular Dysfunctions /  
Occlusion et dysfonctions  
temporo-mandibulaires**  
Dr. Kim Parlett  
Bracebridge, Ontario  
kptooth@muskoka.com



**Occlusion and Temporo-  
Mandibular Dysfunctions /  
Occlusion et dysfonctions  
temporo-mandibulaires**  
Dr. Ian Tester  
St. Catharines, Ontario  
iantester.cardp@cogeco.ca



**Implant Dentistry /  
Dentisterie implantaire**  
Dr. Ron Zokol  
Vancouver, British Columbia  
zokol@interchange.ubc.ca



**Implant Dentistry /  
Dentisterie implantaire**  
Dr. Yvan Fortin  
Québec City, Québec  
yvan.fortin@gmail.com



**Esthetic Dentistry /  
Dentisterie esthétique**  
Dr. Paresh Shah  
Winnipeg, Manitoba  
shahp@mymts.net



**Dental Technology /  
Technologie dentaire**  
Mr. Paul Rotsaert  
Hamilton, Ontario  
paul@rotsaertdental.com



**Practice Management /  
Gestion de pratique  
Dental Materials /  
Matériaux dentaires**  
Dr. Izchak Barzilay  
Toronto, Ontario  
ibarzilay@buildyoursmile.com



**Practice Management /  
Gestion de pratique**  
Dr. Allan Coopersmith  
Westmount, Quebec  
cooperdoc@yahoo.com



**Restorative Dentistry /  
Dentisterie restauratrice**  
Dr. Peter Walford  
British Columbia  
pwalford@telus.net



**Academic Liaison/Liaison  
académique**  
Dr. Peter Taylor  
Oakville, ON  
taydent@aol.com

Publisher:  
Ettore Palmeri, MBA, AGDM, B.Ed., BA  
Palmeri Publishing Inc.  
Toronto, Canada  
ettore@palmeripublishing.com

Office Administrators:  
Sanaz Moori Bakhtiari, B.SC – sanaz@palmeripublishing.com  
Tina Ellis – accounting@palmeripublishing.com  
Bahar Palmeri, B.SC – bahar@palmeripublishing.com

Sales/Marketing:  
Mark Behar Bannelier – mark@palmeripublishing.com  
Gino Palmeri – gino@palmeripublishing.com

Editorial Director:  
Frank Palmeri, H.BA, M.Ed –  
frank@palmeripublishing.com

Production Manager:  
Samira Sedigh, Design Dip. –  
production@palmeripublishing.com

Design & Layout:  
Tim Faller – tim@palmeripublishing.com  
Sophie Faller

Internet Marketing Director:  
Ambianz Inc., Rashid Qadri

Canadian Office:  
35-145 Royal Crest Court,  
Markham, ON L3R 9Z4  
Tel: 905-489-1970, Fax: 905-489-1971  
Email: etторе@palmeripublishing.com  
Website: www.palmeripublishing.com



Articles published express the viewpoints of the author(s) and do not necessarily reflect the views and opinions of the Editorial Board.

All rights reserved. The contents of this publication may not be reproduced either in part or in full without written consent of the copyright owner.

Printed in Canada  
Canadian Publications Mail Product Sale Agreement 40020046

## In this issue / Dans cette édition

Volume 7, No. 1  
Spring/printemps 2014

- 5-6** Guest Editor/Rédacteur Invité  
**34** Call for Papers / Demande de communications

### FEATURES/ARTICLES

#### Fixed Prosthodontics/Prothodontie fixe

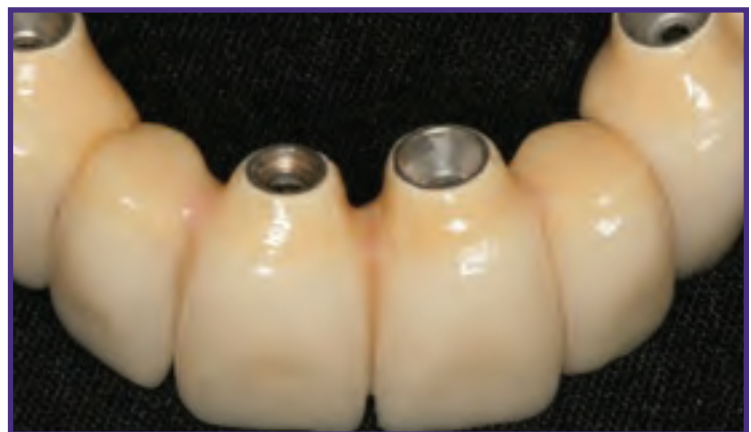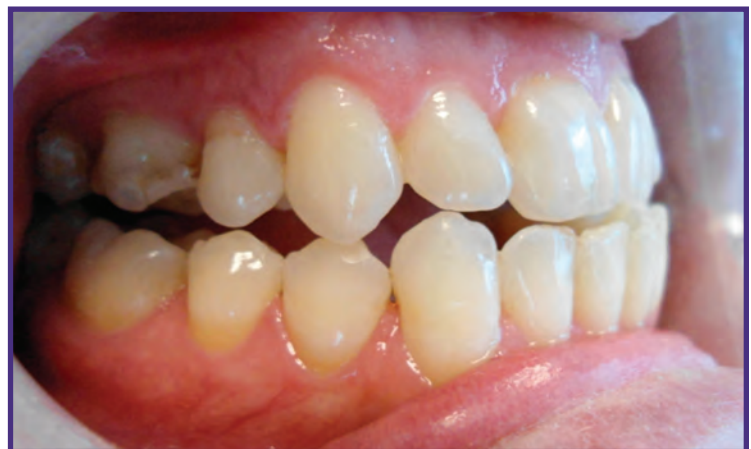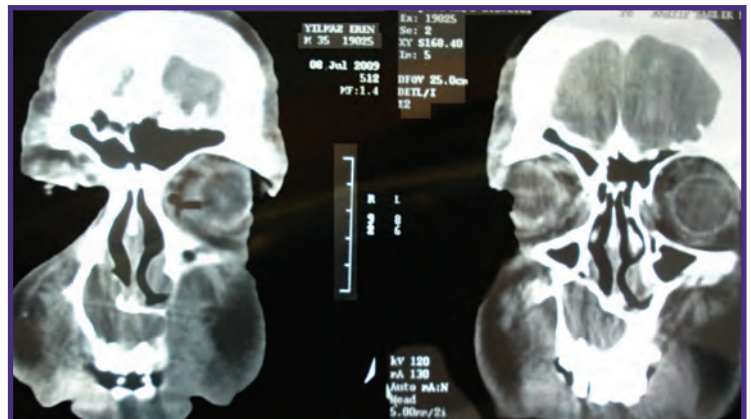
- 08** Management of Soft Tissue with an Emergence Profile Pontic Design for Maxillary Implant-Supported Restorations / Gestion du tissu mou avec conception d'un profile d'émergence de pontique pour des restaurations implanto-portées au maxillaire  
Drs. Yvan Fortin, DMD, Burton Langer, DMD, Richard M. Sullivan, DDS

#### Sleep Dentistry/Dentisterie du sommeil

- 18** Snoring and sleep apnea: what is the role of the general dentist in practical terms? / Ronflement et apnée du sommeil: quel est le rôle du dentiste généraliste dans le processus de prise en charge en pratique?  
Dr David Côté, DMD

#### Implant Dentistry/Dentisterie implantaire

- 30** Minimal Invasive Augmentation with Delayed Tunnel Technique and Rehabilitation of Cyst Patients with Implant Supported Dentures - A Clinical Study/ Augmentation minimale peu invasive avec une technique de tube secondaire et réhabilitation de kystes pour les patients ayant des prothèses sur implants-Étude clinique  
Drs. Engin Aras<sup>1</sup>, Cukurova I.<sup>2</sup>, Sonmez M.<sup>3</sup>, Aladağ A.<sup>4</sup>, Saygi T.<sup>5</sup>, Sahan H.T.<sup>5</sup>



**INDICATES PEER REVIEWED/  
INDIQUE REVUE DES PAIRS**

Cover image/ Photo couverture:  
Marché Bonsecours, Montréal, Qc



Dr. Douglas Hamilton  
Essay Chairman 2014  
douglasshamilton@gmail.com

# CARDP 2014 Annual Meeting - Montréal

## Welcome from our Essay Chairman:

The Canadian Academy of Restorative Dentistry and Prosthodontics (CARDP) holds its Annual Scientific Meetings in various cities across Canada. As part of our mission, we encourage all of the dental community to attend. Anyone who enjoys dentistry and gets excited about learning will love our gatherings.

This year, we have the pleasure to be hosting the Meeting in Montréal, a city that offers its own unique flavors, sights and sounds.

Given that the weather is very pleasant in September, plan on spending some pre or post conference time in this wonderful city. Our Westin Hotel, located in the oldest part of this romantic city, allows for easy access to historic architecture, fine dining and first-rate shopping. You will hear many languages spoken here, but it is the French language that gives Montréal its Québec flavor.

Our social program will introduce you to a Taste of Montréal Tour, Thursday registration Meet and Greet with music and hors d'oeuvres, High Tea at the Queen Elizabeth Hotel, a Shopping Tour, and of course, our Gala Dinner Dance on Saturday.

Our scientific theme, Tomorrow's Dentistry Today, will emphasize leading edge diagnostics, treatment planning, and restorative treatments.

This year, we are putting forward two hands-on, pre-meeting courses: the first will address Forward Endodontics, while the second gives attendees the opportunity to experience all tissue Waterlase applications.

Friday will see a very strong speaker lineup at the podium, on a broad range of topics: implant prosthetic options, sleep apnea, bruxism and facial pain, digital dentistry, digital lab case planning and prototype guided prosthetics, planning resection versus augmentation in site preparation of the edentulous maxilla, and finally, analysis, planning, surgical and prosthetic options for the edentulous maxillary arch.

The Saturday morning short format lectures will cover:

material selection in colour matching of ceramic restorations on discoloured teeth, peri-implantitis, laser assisted new attachment procedure, cone beam assisted digital implant treatment planning, restorative precision with ceramic systems, implants versus endodontic treatment, and a feature on how our Canadian Military helps abroad with field dentistry.

Moreover, we are delighted to provide our attendees with presentations in both official languages as well as simultaneous translation.

Our program includes a full complement of table clinics. Some highlights are endodontic techniques, photography in colour matching dark stained teeth, cone beam guided implant placement, prototype guided prosthetics, a new contoured matrix system for foolproof contacts in composite resin placement, demonstration of the Canadian Dental Corps field operations unit and many more.

As usual, we have a commercial component to our Meeting where you can discuss with some of your favorite product representatives, in a more relaxed and intimate setting, the products and issues you find interesting.

We are a collection of dedicated restorative and prosthodontic dentists from all across Canada who believe in a congenial, interactive atmosphere to share our knowledge and passion for excellence. Join us for an exciting experience that will open windows of learning and transform your professional life as it has ours.

For information on the CARDP Montréal Meeting and registration, please visit [www.cardp.ca](http://www.cardp.ca)

See you in Montréal!

Dr. Douglas Hamilton  
Guest Editor  
Essay Chairman 2014  
douglasshamilton@gmail.com



Dr Douglas Hamilton  
Essay Chairman 2014  
douglasshamilton@gmail.com

# Congrès annuel ACDRP 2014 – Montréal

## Mot du Président du programme scientifique

L'Académie canadienne de dentisterie restauratrice et de prosthodontie (ACDRP) tient son congrès annuel dans différentes villes à travers le pays. Notre mission est d'encourager la communauté dentaire à y prendre part. Tous les fervents de la dentisterie et du savoir y trouveront leur compte.

Cette année nous avons le plaisir d'accueillir notre congrès à Montréal, une ville unique de par ses saveurs, ses attraits et ses rythmes.

Étant donné la température agréable du mois de septembre, pourquoi ne pas planifier un pré ou post congrès dans cette merveilleuse métropole? Notre hôtel Westin, qui est situé dans le vieux Montréal romantique, permet un accès facile aux édifices historiques, aux bonnes tables ainsi qu'au lèche-vitrine hors pair. Ici, vous distinguerez plusieurs langues parlées, mais c'est le français qui confère à Montréal son cachet québécois.

Notre programme social vous proposera une tournée avant-goût de Montréal, une rencontre avec musique et hors d'oeuvres lors de l'inscription du jeudi, High Tea au Reine Élisabeth, une randonnée dans des boutiques, et bien sûr, notre dîner gala du samedi.

Notre thème scientifique: Atteindre la dentisterie du futur, mettra en valeur les progrès en diagnostic, la planification des traitements, et les traitements restaurateurs.

Cette année nous mettons de l'avant deux cours pratiques pré-congrès: le premier porte sur la fine pointe de l'endodontie tandis que le deuxième permet aux participants d'expérimenter les applications tissulaires du Waterlase.

Le vendredi, une panoplie de sujets sera présentée par des conférenciers chevronnés: options prothétiques en implantologie, apnée du sommeil, bruxisme et douleurs faciales, dentisterie numérique, planification numérique des cas de laboratoire et fabrication de prothèses à l'aide de prototypes, planification des résections versus l'augmentation du site opératoire des maxillaires édentés, et finalement, analyse, planification, options chirurgicales et prothétiques du maxillaire édenté.

Les présentations abrégées du samedi matin discuteront de: la sélection des matériaux afin d'assortir la couleur des restaurations céramiques aux dents décolorées, péri-implantite, régénération de nouveaux attachements à l'aide du laser, plan de traitement

numérique des implants assisté par faisceau conique, la précision restauratrice au moyen de systèmes céramiques, implants versus endodontie, et une présentation sur les interventions dentaires de première ligne de nos militaires canadiens à l'étranger.

Nous sommes heureux d'offrir à nos participants des conférences dans les deux langues officielles en plus de la traduction simultanée.

Notre programme inclut un ensemble de démonstrations cliniques portant sur des sujets tels: des techniques en endodontie, l'utilisation de la photographie pour allier les décolorations foncées des dents, le placement des implants assisté par faisceau conique, la fabrication de prothèses à l'aide de prototypes, un nouveau système de matrice adapté pour l'obtention de contacts optimaux des restaurations en composite, la démonstration des opérations du corps dentaire canadien en première ligne, et beaucoup plus.

Comme toujours, notre congrès inclut un volet commercial qui encourage l'interaction avec les fournisseurs dans un contexte détendu.

Nous sommes une collectivité de dentistes en Restauration et Prosthodontie du Canada entier qui prônons un milieu chaleureux pour échanger nos connaissances et notre passion pour l'excellence. Soyez des-nôtres pour vivre cette expérience enrichissante qui vous révélera de nouveaux horizons et transformera votre vie professionnelle.

Pour des renseignements sur le congrès de l'ACDRP à Montréal et l'inscription, veuillez saisir: [www.cardp.ca](http://www.cardp.ca)

Au plaisir de vous voir à Montréal!

Dr Douglas Hamilton  
Rédacteur Invité  
Président du programme scientifique  
douglasshamilton@gmail.com

*Expérience et performance*  
**LE PARFAIT ALLIAGE.**



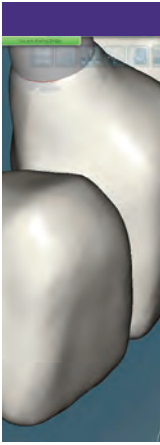
PROTHÈSES FIXES ET AMOVIBLES / FLEXI NYLON / IMPLANTS / CAD TITANE  
CAD CAM / TRAVAUX MIXTES / RONFLEMENTS ET APNÉES / PROTHÈSES ESTHÉTIQUES

Grâce à la formation continue de notre personnel et à l'utilisation de technologies de pointe, nos produits sont d'une qualité indéniable et répondent aux exigences les plus pointues.  
Découvrez tous nos services sur [lafonddesjardins.com](http://lafonddesjardins.com) ou par téléphone au 450 669-9221 / 1 800 361-2145



**LAFOND DESJARDINS  
& ASSOCIÉS INC.**

LABORATOIRE DENTAIRE



## Management of Soft Tissue with an Emergence Profile Pontic Design for Maxillary Implant-Supported Restorations

### Gestion du tissu mou avec conception d'un profile d'émergence de pontique pour des restaurations implanto-portées au maxillaire



Yvan Fortin, DMD  
(Private Practice, Montreal, Quebec),  
Burton Langer, DMD  
(Private Practice, New York, New York),  
Richard M. Sullivan, DDS  
(Vice President, Clinical Technologies,  
Nobel Biocare Americas)

#### Abstract

**Background:** Currently the two most prevalent pontic designs for anterior esthetics are the modified ridge lap and ovate types. This article describes a new, mildly compressive design that follows the contours of the residual osseous ridge crest and displaces more of the soft tissue into the labial, palatal, and interproximal areas, better reproducing a natural tooth-emergence profile.

**Methods:** As the actively directed soft tissue flows into the proximal areas and circumferentially over the pontic line angle borders, a lack of through-and-through access from labial to palatal results. To avoid disrupting the pontic/soft tissue interface, patients are instructed not to floss. Instead they need only brush their teeth for routine oral hygiene, a regime that most patients can easily maintain. **Results:** The authors have documented long-term (up to 15 years) maintenance of the soft-tissue health under Emergence Profile Pontics (EPPs).

**Conclusion:** When sufficient residual soft tissue volume is available, this design can be recommended for pontics supported by both natural tooth and implant abutments in esthetic areas.

**Key words:** pontic, papilla, compression, emergence profile, hygiene

#### Introduction

In the history of pontic development and tissue management associated with crown-and-bridge rehabilitation, a longstanding objective has been to avoid any compression of the soft tissue that might result in blanching, blood-supply compromise, and necrosis of the compressed tissues. Another concern has been to allow dental hygiene access for periodontal health.<sup>1,2</sup> Esthetic results can be challenging to achieve with pontics because tooth extraction often is associated with hard- and soft-tissue site resorption. The reduced residual tissue volume can make it difficult or impossible to reproduce the ideal gingival contours associated with the cervical-labial area of the tooth or teeth being replaced.<sup>3,4</sup> Even if implant placement has been optimal and the optical properties

and other characteristics of the prosthetic restoration are excellent, if the relationship between the soft-tissue interface relative to both implant crowns and any intervening pontics is not harmonious, both the esthetic outcome and long-term hygienic maintenance may be compromised.

The types of pontics used in fixed partial dentures have evolved gradually over the years. Early pontic were sanitary, allowing easy access for brushing. But they had little esthetic appeal. Saddle pontics (Figure 1a) that approximated the ridge crest were able to give the illusion of a tooth emerging from the ridge but have largely been abandoned due to the oral hygiene compromise associated with their design. To meet growing demand for a more esthetic alternative, ridge-lap pontics were



**Contexte :** Actuellement, les deux formes les plus répandues de pontique pour les dents antérieures, du point de vue esthétique, sont du type de chevauchement modifié de la crête et du type ovale. Cet article décrit une nouvelle conception, légèrement plus compressive, qui suit les contours osseux restants de la crête, et déplace plus de tissu mou dans les régions labiales, palatines et interproximales, de manière à reproduire un profil d'émergence plus naturel de la dent.

**Méthodes :** Étant donné que le tissu mou est activement déplacé dans les régions proximales et en circonférence, au-delà des limites de la ligne d'angle du pontique, il en résulte un manque d'accès du labial au palatin. Pour éviter d'entraver l'interface pontique/tissu mou, on demande aux patients de ne pas utiliser la soie dentaire. Plutôt, ils doivent se brosser les dents pour leur hygiène orale quotidienne, une routine que les patients peuvent facilement respecter.

**Résultats :** Les auteurs ont documenté le maintien à long terme (jusqu'à 15 années), de la santé du tissu mou, utilisant le Profile d'Émergence de Pontiques (PEPs).

**Conclusion :** Lorsqu'un volume suffisant de tissu mou résiduel est disponible, cette conception peut-être recommandée pour des pontiques supportées soit par des dents naturelles ou par des piliers d'implants dans les régions esthétiques.

**Mots clé :** pontique, papille, compression, profil d'émergence, hygiène

developed that extended the cervical margins labially (Figure 1b). This allowed the host tissue to be visible interproximally, resembling a papilla. Although more visually appealing, ridge-lap pontics required the use of floss or other adjunctive measures to thoroughly clean under the bridge. Recently Kim, Cascione, and Knezevic described using a ridge-lap pontic design that compresses tissue circumferentially with the strategy of displacement to develop "pseudo" interdental papillae.<sup>5</sup>

Ovate pontics represent another attempt to produce natural looking pontic emergence.<sup>6-13</sup> The tissue-contacting surface of this design is convex relative to the soft tissue (Figure 1c), compressing it against the ridge crest. Soft tissue outside the area under compression is displaced away from the pontic. Although this creates a true initial emergence from the pontic site, it does not add to vertical papilla height.

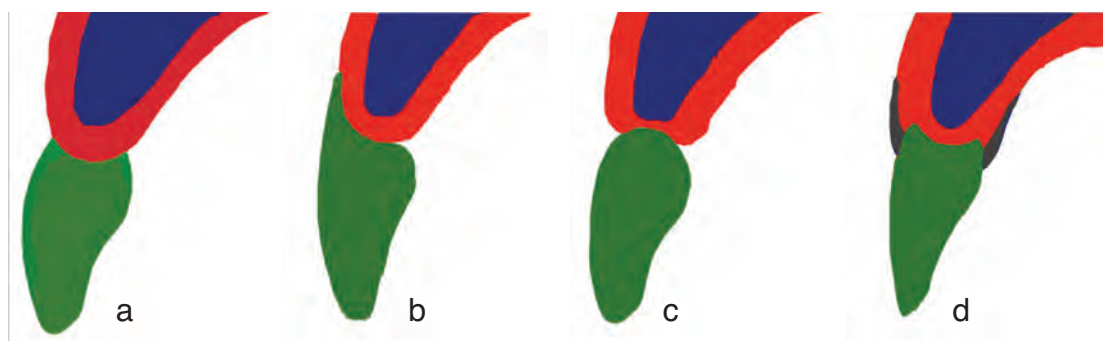


Figure 1a: Saddle pontics can be esthetic but have largely been abandoned due to the oral hygiene compromises they require.

Figure 1b: Ridge-lap pontics require a significant patient commitment to oral hygiene maintenance.

Figure 1c Although ovate pontics initially create the appearance of a true emergence form the pontic site, they do not add to the vertical papillary height.

Figure 1d: The Emergence Profile Pontic design uniformly compresses the tissue, paralleling the residual osseous ridge crest and displacing soft tissue over the pontic line angle borders. In this illustration, the gray areas represent labial and palatal tissue displaced by compression.

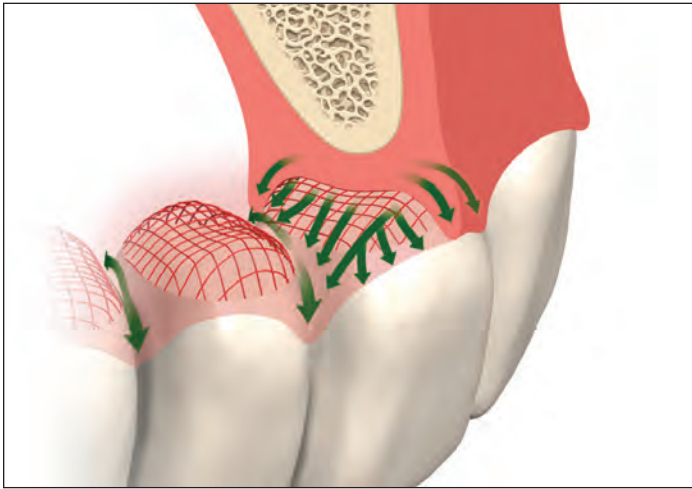


Figure 1: Illustration showing gingival tissue recontouring with the use of an Emergence Profile Pontic.

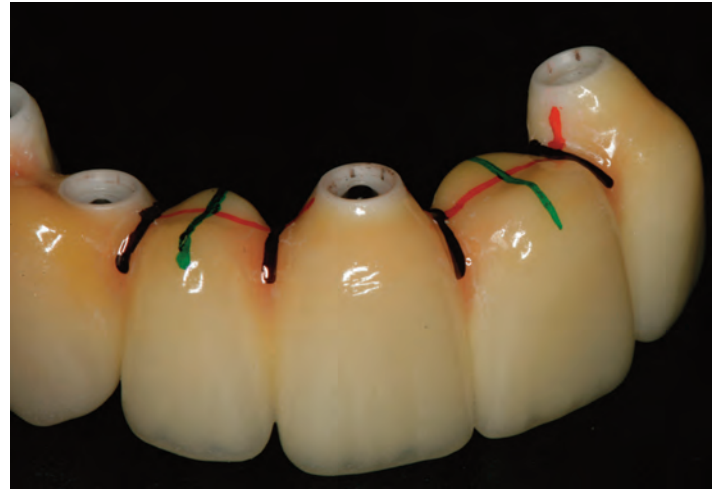

Figure 2: The Emergence Profile Pontic design simultaneously directs tissue from the midcrestal position toward the interproximal, labial, and palatal areas by selective compression of available soft tissue. The labial-palatal contours are concave in the center and convex as they approach the labial and lingual, roughly mirroring the contours of the osseous ridge crest. The plane from mesial to distal (red) is convex throughout the tissue-contacting surface of the pontic body. The proximal connections (black) are convex to effectively direct the flow of the compressed tissue toward the labial and the palatal proximal areas in the shape of a papilla.

Luc and Patrick Rutten have listed primary objectives for the use of ovate pontics<sup>14</sup> that could as well apply to pontics in general. These objectives include:

- Achieving a natural look that is undetectable as a dental restoration.
- Creating the most natural emergence profile possible. The bridge pontic should look like it is growing out of the gingiva, with the gingiva and crown(s) in alignment.
- Bridge pontics should not retain pieces of food.

The aim of this article is to present an alternative pontic design that was developed over a 15-year period for maxillary screw-retained dental-implant-supported restorations. This design includes not only the pontics themselves but also all intervening connections to redistribute the entire three-dimensional soft-tissue volume dynamically and esthetically, without compromising the oral hygiene or causing tissue inflammation.

### The Emergence Profile Pontic

The Emergence Profile Pontic (EPP) (Figure 1d) was developed to apply pressure in a selective and strategic manner to the underlying soft tissue, directing the compressed tissue to flow into the surrounding areas in such a way as to reproduce a natural looking tooth-emergence profile, while maintaining tissue health. Achieving this requires a more complex topography than that embodied in

earlier pontic designs. As Figures 2a and b illustrate, the labial-to-palatal (or labial-to-lingual) contours of the pontic body (illustrated by the green lines) are concave in the center and convex as they approach the labial and lingual, roughly mirroring the contours of the osseous ridge crest. This shape is intended to compress the soft tissue uniformly against the residual bone crest. (Typically the height of the soft tissue between the pontic and the bone crest is reduced by 1.5mm; under no circumstances should the compression reduce the tissue height by more than half.) The compression displaces the soft tissue toward the entire pontic periphery – labial, palatal, and proximal.

The mesial-to-distal contours of the EPP, illustrated by the red lines, are convex throughout the tissue-contacting surface of the pontic body. This convexity echoes the facial appearance of a natural tooth as it emerges from the soft tissue (longer in the mid-cervical area and shorter at the interproximal junctions). But it differs significantly from the mesial-to-distal convexity of the ridge-lap pontic depicted in Figure 1b; that mesial-to-distal convexity only involves the portion of the pontic covering the labial aspect of the ridge.

The third important element of the EPP design is the shape of the labial-to-palatal junction between the pontic and the elements adjoining, either other pontics or implant-supported crowns

**VIVACLAIR CANADA**

PRESENTS

**Zirclair™**

ZIRCONIA REDEFINED

by

*Rossan Halladay*



**QUALITY IS OUR SIGNATURE**

A full service dental laboratory offering: a milling center facility,  
fixed bridges, crowns and veneers, removable dentures,  
metallic partials, implants and titanium prothesis.



1 Place du Commerce, # 415  
Ile des Soeurs, (Qc) CANADA H3E 1A2

**T 514.582.7178 / 514.766.3777**  
1 866.921.VIVA (8482) / F 514.766.3377  
order@vivaclair.ca / www.vivaclair.ca

(illustrated by the black lines in Figure 2a). Unlike the centrally concave labial-to-palatal pontic body contours, the junctional contour is uniformly convex, with the contour peaking in the middle of the connection. This shape creates additional space on the labial and palatal sides of the pontic into which the compressed soft tissue can flow, while applying some additional compression to direct the soft-tissue volume to the labial and palatal in the papilla area.

To achieve optimal results, it is helpful to understand the cross-sectional anatomy of the edentulous site receiving an EPP, as well as the dynamics of blood flow as tissue is compressed and redirected. When gingival tissue is compressed, it does not simply disappear. Instead, tissues are displaced by the source of compression, gradually adapting to it as long as adequate vascularization is maintained. Should vascularization be inhibited by compression for too long, varying degrees of tissue necrosis will ensue. In contrast, when compression is minimal and controlled, local circulation and tissue oxygenation resume, and capillary remodeling occurs, leading to vascular remodeling.<sup>15</sup> Depending on the situation, harmonious vascular remodeling and reorganization of the tissue mass may require successive phases of compression and relaxation until the pontic is in its final position, and the tissues are properly vascularized through newly formed shunts.<sup>16,17</sup> When this occurs, the color of the compressed tissue will again match that of the surrounding tissue.

The following section describes the steps necessary to create a maxillary screw-retained porcelain-to-zirconia bridge incorporating EPPs.

### Clinical preparation of patient

It is recommended that impressions be performed only when the soft tissue is stable, whether following delivery of a provisional

restoration or healing abutments. The impression may be made at the implant or abutment level, following the principles for precise-fitting screw-retained implant restorations. The authors' experience has been limited to open-tray impressions with splinted non-engaging impression copings or non-engaging titanium cylinders. The impression is made over the luted cylinders or impression copings and is removed as one unit.

### Dental laboratory procedure

The first pour of the impression with appropriate implant or abutment replicas attached is for production of a scanning model to be used in the framework-production process. This is made with impression plaster, following the manufacturer's directions. A second pour of the impression with new replicas is then made with the possibility for removable soft tissue to be incorporated into the model for mounting and overall framework design. A third pour of the impression with replicas is then made, with the edentulous areas that will receive the pontics reproduced in solid stone.

The restoration framework is then designed, either virtually on a computer or as a resin prototype to be scanned (Figure 3a). The soft-tissue-contacting areas of the pontics are refined to create optimal emergence profiles from the ridge crest for the intended restorations (which at this point resemble saddle pontics or the underside of denture teeth). The tissue-contacting area should roughly follow the curvature of the residual ridge crest, as produced on the solid stone model. The connections of the pontics either to other pontics or to the implant- or abutment-retained elements are designed as described above with the convex contour peaking in the middle of the connection. The apex of this convex contour should extend as far toward the ridge crest as the emergence-profile contours of the restoration design will allow.

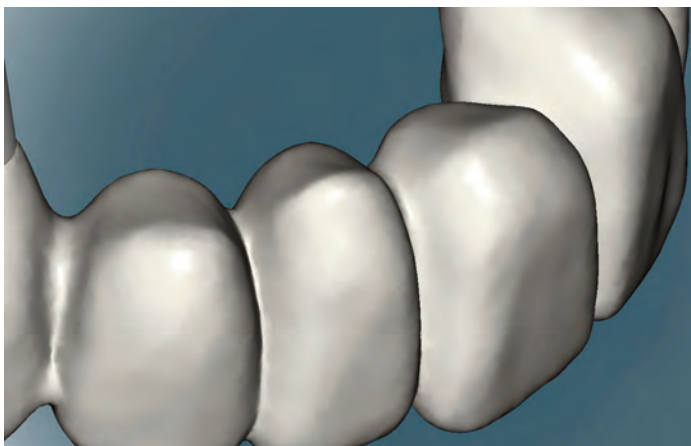


Figure 3a: The restoration framework is designed either virtually or by scanning an acrylic design. The EPP contours are designed with proper emergence to the solid cast.

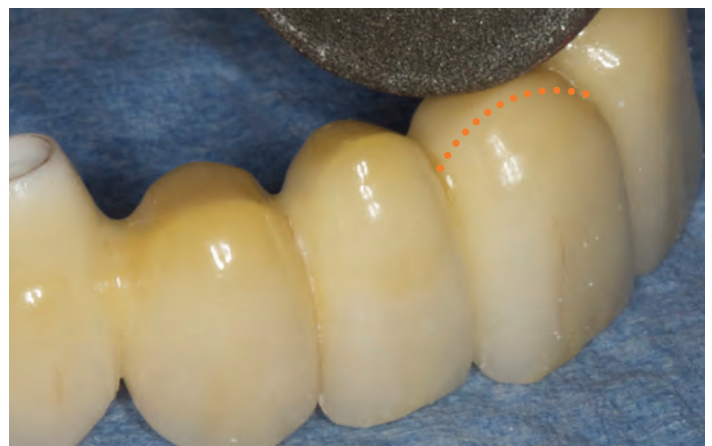

Figure 3b: After the framework is produced in zirconia, porcelain is added to the tissue-contacting surface. The final contours are refined with a disc.

Torq Control  
Torq Control®



# Implant Solutions

Your one stop solution for all your implant needs

## Specializing in:

- Bone Grafting Instruments
- Bone Grafting Material
- Extraction Elevators & Forceps
- Infection Control & Draping
- Irrigation & Tubing

- Handpieces & Bone Saws
- Measuring Devices
- Periosteal Elevators
- Periotomes
- Retractors

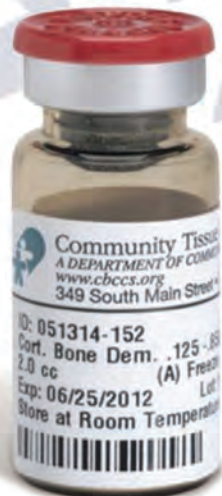- Rongeurs
- Sinus Lift Instruments
- Surgical Sundries
- Torque Wrenches & Drivers
- And more...

[www.implant-solutions.com](http://www.implant-solutions.com)

1.877.857.8333

Call to receive our  
2014 Catalogue!

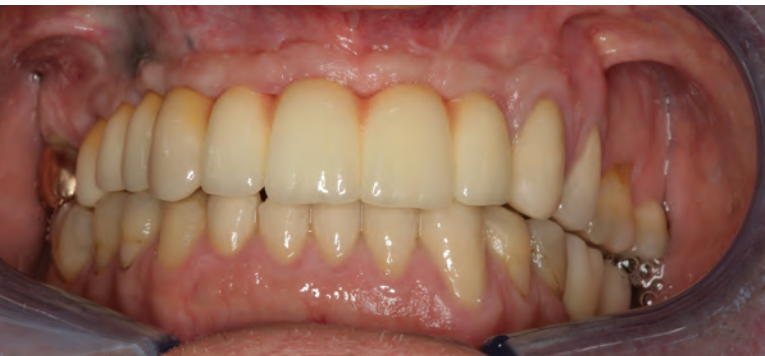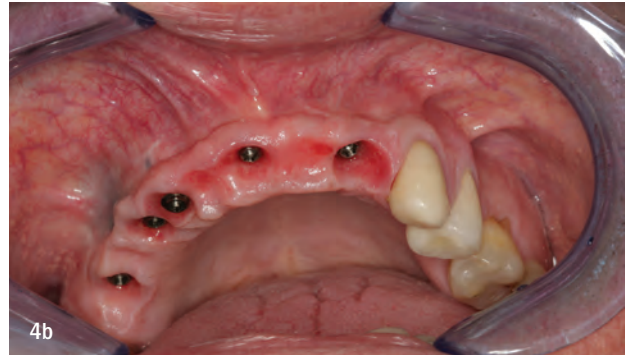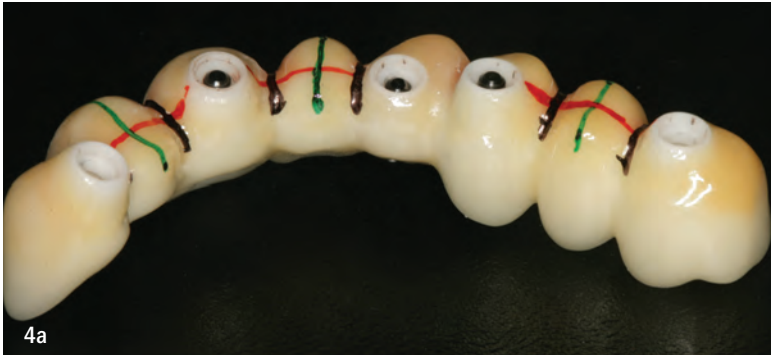Bone Carrier



Allograft Bone

Surgical Implant Drape Kit





**Figure 4c:** Emergence profile pontic design with labial and interproximal displacement of tissue. Compressed depth to half the distance to the residual ridge crest with observant delivery will maintain vitality of the soft tissue and bone while redistributing soft tissue where directed by the pontic contours.

**Figure 4a:** Porcelain to zirconia implant-level restoration marked to show tissue compression strategy. Green demonstrates pontic concavity, red pontic convexity, and black connection convexity to tissue surface.

**Figure 4b:** Soft tissue immediately upon removal of porcelain to zirconia restoration adjacent to natural teeth. The bridge has been in place for 3 months and was removed for photographic demonstration purposes only. No oral hygiene other than toothbrush has been used, as access under bridge is impeded by soft tissue. Continued growth of interproximal tissue resembling a papilla can be expected to improve over time.

The framework is now ready for fabrication in zirconia. When the completed framework is returned to the laboratory, the patient is scheduled for try-in. Because there is no compression at this time, the framework should seat fully, with radiographic confirmation. Once full seating has been established, long guide pins are substituted for prosthetic screws. The framework is then picked up in an open tray impression to produce a new cast relating the framework to the soft tissue. This new cast aids in precise addition and contouring of porcelain relative to the soft tissue.

The technician then applies the normal esthetic veneering and adds porcelain to the pontic compression areas. In adding the porcelain, it should be kept in mind that tissue will be directed from the area of most compression toward the areas of relief. Although the center of the pontic will compress the most, within that central area, the intention is to uniformly compress the soft tissue against the resistance of the typically convex alveolar crest by paralleling it with the concave pontic surface.

The process then continues with porcelain added in lesser amounts on either side of the central compressive area (similar in concept to the development of “blunted” triangular ridges on maxillary premolar cusps). This introduces both a labial and palatal convexity to the pontic underside, with both planes sloping toward each other to produce a concavity that continues to parallel the

ridge. Again, this serves to concentrate the compression in the center of the pontic, with lesser amounts of compression applied to the soft tissue as it is directed toward the proximal connections. The simultaneous compression of the sloping pontic interface and the apical convexity of the connections redirects tissue toward the relieved open areas, thus forming papillae. Tissue also flows circumferentially over the pontic border, submerging it within a soft tissue cuff. The fact that the soft tissue is moved to now overlap both pontic borders and connections creates a situation in which traditional oral hygiene using an implement is no longer possible because of the lack of direct through-and-through access.

At this point, the framework will no longer seat on the solid cast, so a cast with removable soft tissue must be used for further mounting procedures. After firing, the pontic area is contoured with a wheel (Figure 3b) to refine the mesial/distal convexity that will direct the flow of the soft tissue toward the entire periphery – interproximally as well as labially and palatally. (Figures 4 a-c)

### Clinical procedure

Because the EPP Pontic is overextended apically relative to the current soft-tissue crest, it cannot be expected to seat fully on the first attempt. After initial placement of the bridge and gentle fastening against the resistant soft tissue, blanching typically

occurs. After 10 minutes, the bridge is loosened for two to three minutes to allow blood to re-penetrate the compressed area. This sequence is then repeated three to four times. The blanching should gradually lessen, indicating progressive adaptation of the soft tissue to the pontic, with normal gingival color returning by the end of the visit (Figures 5 a-f).

In the event of blanching continuing for an extended period (more than an hour), the clinician may choose between three alternatives:

- 1) Modify the bone underlying the pontic site.
- 2) Modify the underside of the pontic.
- 3) Insert a needle into the blanched area to stimulate new blood supply through angiogenesis.<sup>18-20</sup>

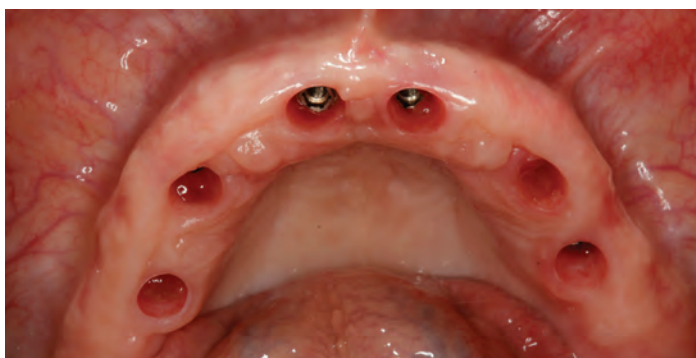

Figure 5a: Flat tissue topography before initial placement of a screw-retained porcelain-to-zirconia restoration with EPPs.

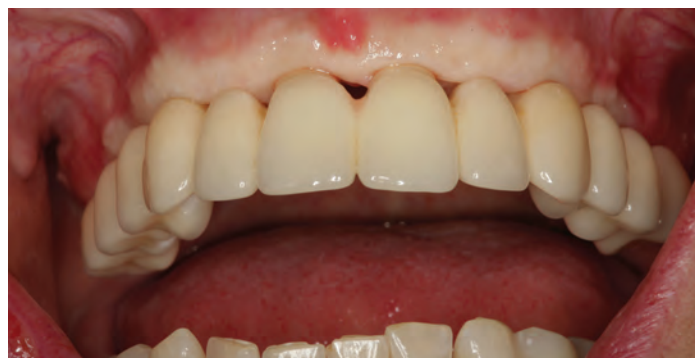

Figure 5b: Initially, the bridge cannot be fully seated, with obvious blanching due to the tissue compression. The bridge is loosened to allow blood to repenetrate and then seated again. This process is repeated until full seating on implants occurs.

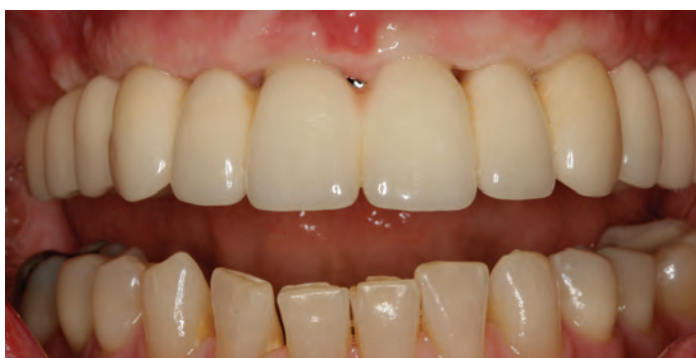

Figure 5c: Approximately one hour after initial bridge delivery, the bridge has been fully seated with minimal blanching, and the patient can be discharged. Papilla fill will occur over the next several months. The patient will maintain oral hygiene with brushing only.

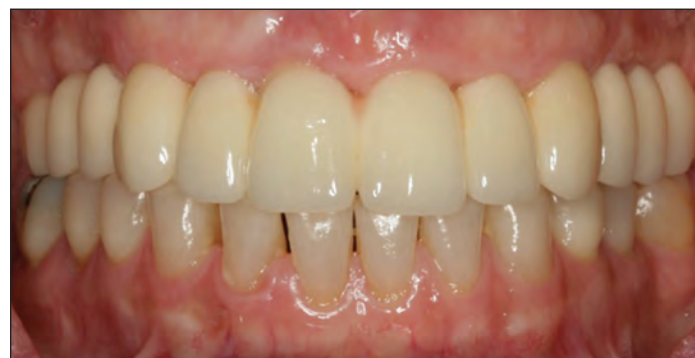

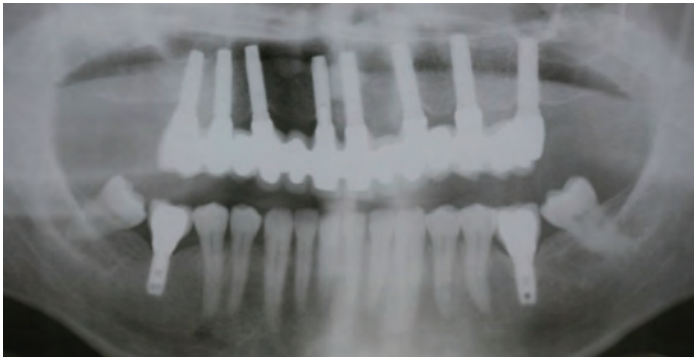
Figure 5d: Six months later, the EPPs have created a highly natural soft-tissue appearance around the bridge, which has not been removed since the initial delivery.

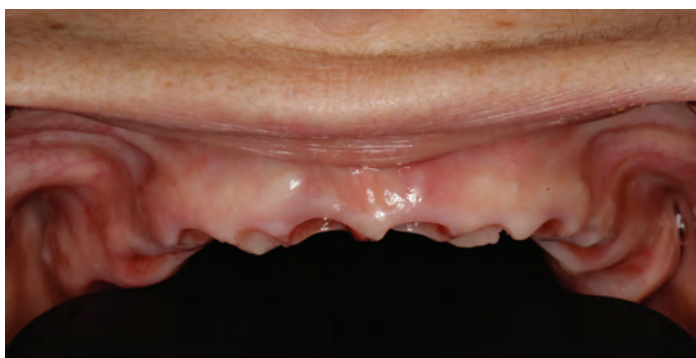

Figure 5e: Facial view of the soft tissue after removal of the bridge (for photographic purposes only) six months after delivery.

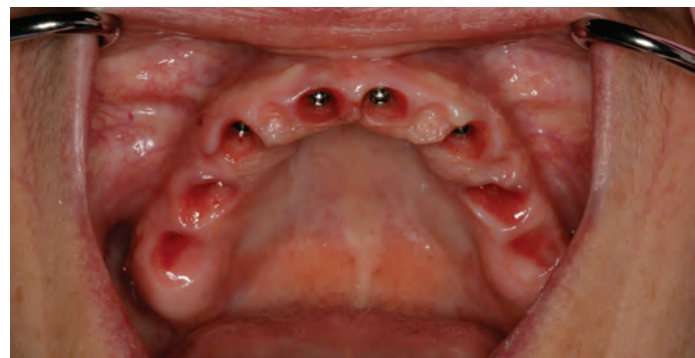
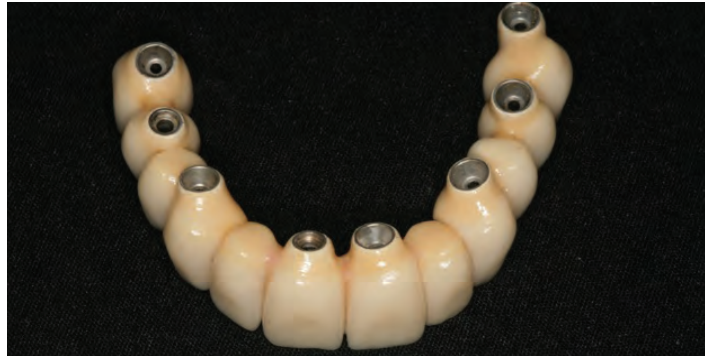
Figure 5f: The occlusal view of the soft tissue six months after delivery of the bridge with EPPs compares strikingly with the appearance of the tissue in Figure 5a.



Figures 6a-6c: Ten-year follow-up of Emergence Profile Pontic design. Porcelain-fused-to-gold was previously used before zirconia. The restoration, which was removed for investigative and photographic purposes only, had been in place for 10 years and was maintained with toothbrush only.

Figure 6b

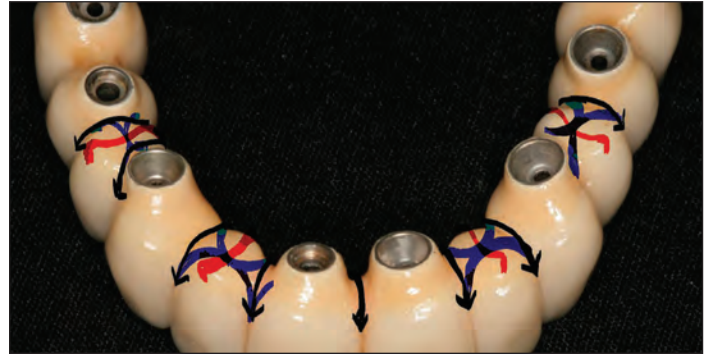
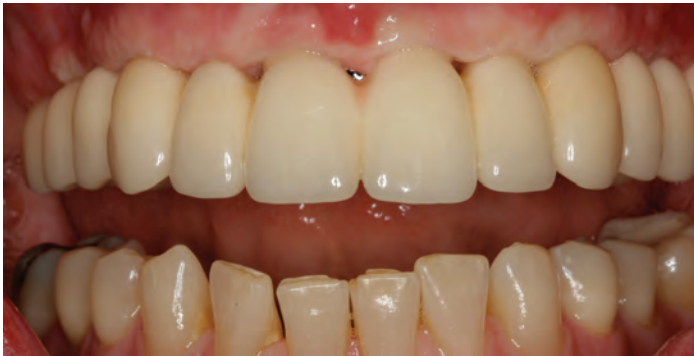

Figure 6c

Figure 6d: EPP design with computer graphics superimposes to accentuate the contours, including the interproximal connection concavities (in black).

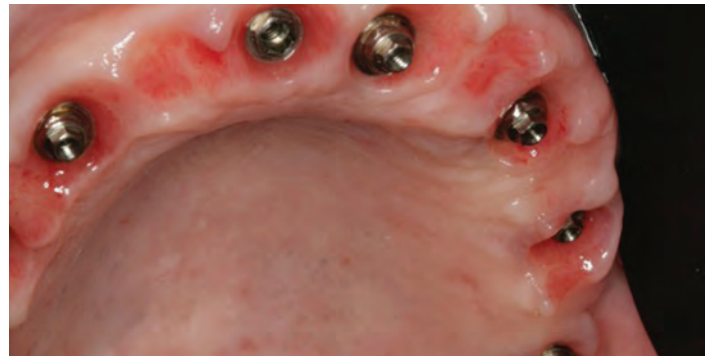
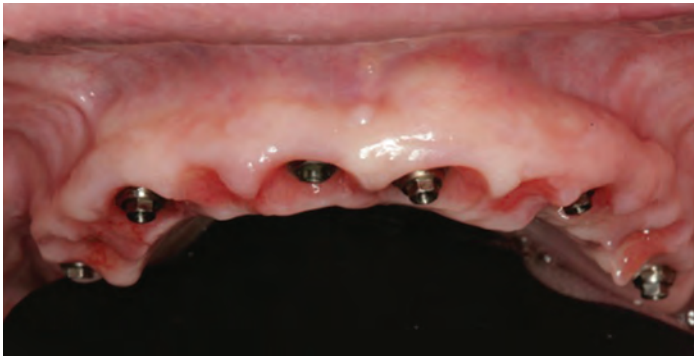
Figure 6e-6f: soft tissue appearance under EPP designed maxillary bridge

Figure 6f

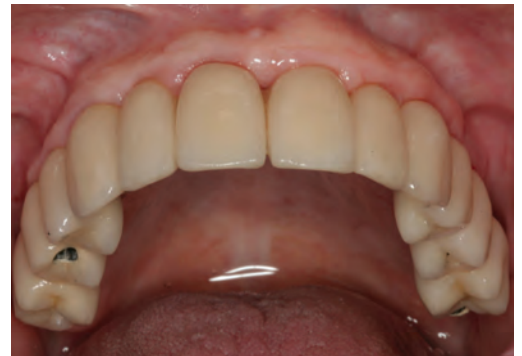
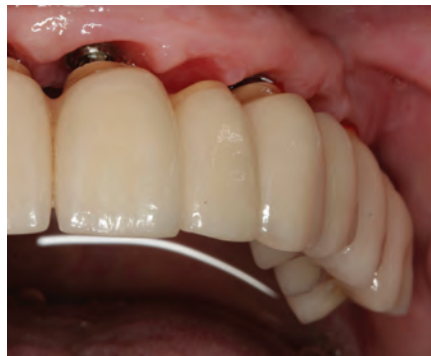
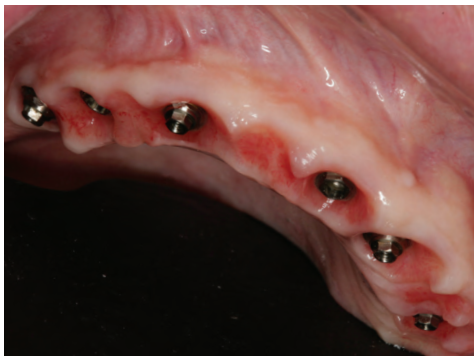Figure 6g: Upper left quadrant, photographed before restoration was re-seated.

Figure 6h: Restoration suspended before final seating to show interproximal adaptation of soft tissue.

Figure 6i: Restoration re-seated before screw access-hole closure.





Experience CAMLOG live!  
[www.camlog.com](http://www.camlog.com)



Excellent Tube-in-Tube™  
connection

Fast, secure positioning through  
three grooves and cams

Millionfold proven SCREW-LINE  
outer geometry

Alternatively with  
platform-switching

High radial  
position precision

Template-guided implantation  
as an option

# SUCCESS

The CAMLOG® Implant System has been a genuine success story since 1999. Its outstanding user-friendliness, first-rate precision, and coherent prosthetic orientation have convinced more and more users. Rounding off its overall offer with an exceptional price-performance ratio, CAMLOG has become the trusted supplier of choice for numerous implant professionals. Go and see for yourself: [www.camlog.com](http://www.camlog.com)

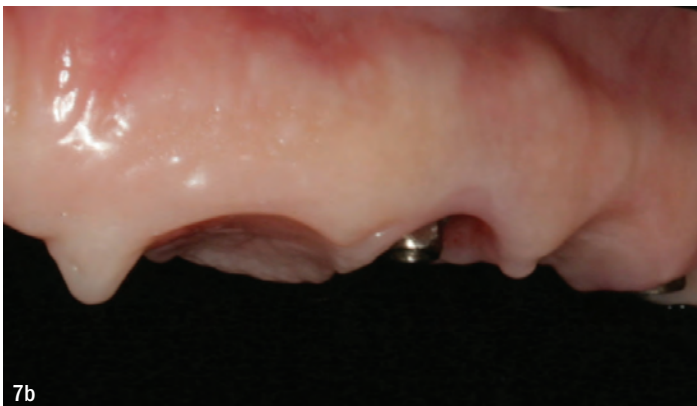
CAMLOG stands for success.

a perfect fit™

camlog

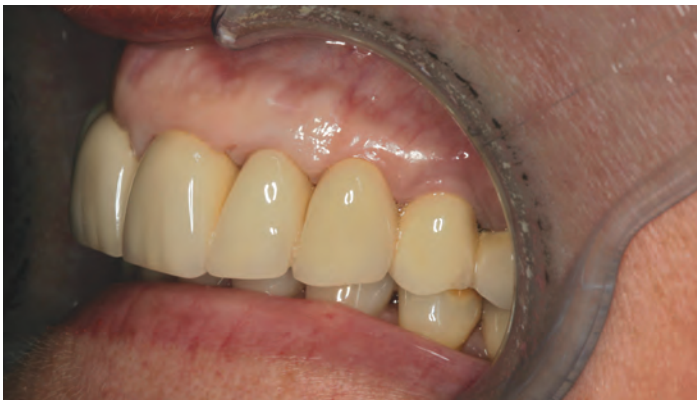
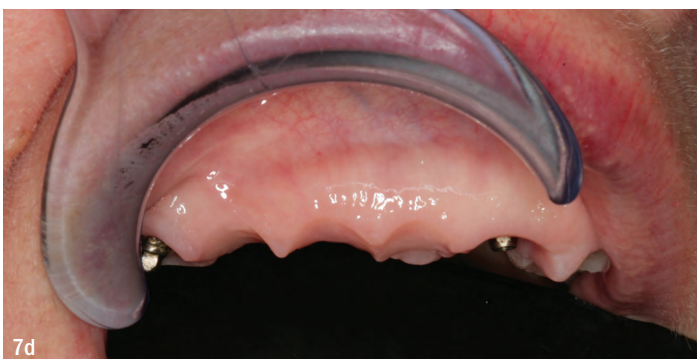
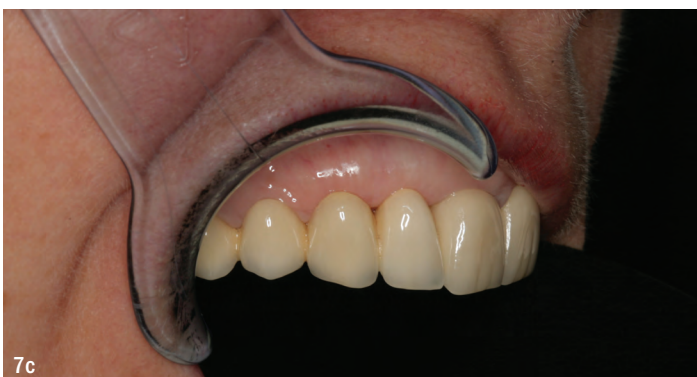Figure 7a: Implant restoration with EPPs at 15-year follow-up.



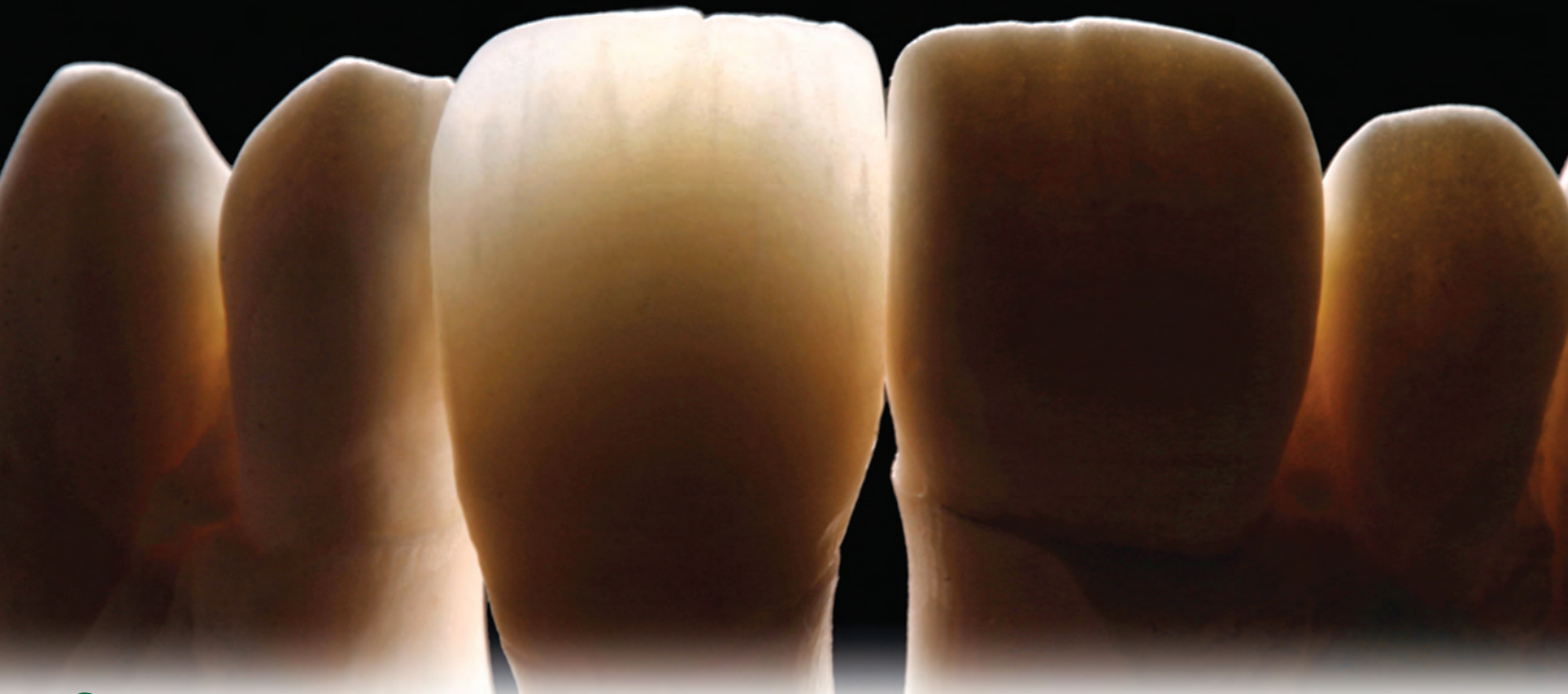Figures 7b-d: Appearance of the soft tissue immediately after bridge removal for photographic purposes only. This restoration had been in place for eight years since the previous removal. No cleaning of the restoration or soft tissue has been performed.

In any event, to avoid over-compression, the return of blood flow after the blanching process must be observed before the patient is discharged.<sup>21-23</sup> The patient leaves with instructions that only a toothbrush (manual or electronic) is to be used for oral hygiene. The gingiva will continue adapting to the pontic contours throughout the ensuing year, with tissue directed to the labial, palatal, and interproximal areas. The authors have documented long-term (up to 15 years) maintenance of the soft-tissue health under EPPs, in the absence of specific hygiene measures directed at this junction (Figures 6a-i, Figures 7 a-d).

## Discussion

Tooth extraction in the esthetic zone often leads to a soft-tissue deficit affecting both the labial tissue volume and papillae adjoining any pontic teeth. Given that tissues are displaced by pontics during compression, it is advisable to orient the displacement toward zones that require additional tissue. The design of the EPP described in this article results in relatively significant displacement of tissues directed toward the labial and proximal areas of the pontic crown. To enhance the illusion that these tissues are framing a real tooth that has grown naturally into place, rather than a synthetic substitute, it is important that the facial surface of the pontic be oriented along the same axis as the natural tooth being replaced. To accomplish this, a defined line angle is created between the pontic underside and the labial surface that is less than 90 degrees. An equivalent or very similar angle is created at the junction of the palatal surface to the pontic underside. Through clinical and/or empirical observation, it has been found that this angle encourages—or at least does not interfere with—tissue adaptation and restructuring over these line angles of the pontic itself in addition to tissue volume directed to the interproximal areas.

The observed response shows that provided the vascularity of residual attached soft tissue is not compromised, the position of the residual tissue will move in response to direction while rapidly developing new blood supply to compensate for the compromise introduced by the compression. Keeping in mind the morphology of teeth, ever efficient at repositioning food during mastication away from the stamping cusps through sluiceways created by triangular ridges and embrasures, the pontic underside similarly nudges the tissue along a similar path (Figures 8a and b). That this repositioning is maintained is not surprising, since highly scalloped soft tissues underneath pontics have been observed for decades when fixed partial dentures supported by teeth have been removed either for replacement or dental extraction. These observations have included many pontic sites of high tissue health that have not had a history of routine oral hygiene maintenance. These findings demonstrate that the restorative undersides of framework pontics and supporting abutments, at the present and proposed soft-tissue



## STRIVING FOR PERFECTION AND ACHIEVING EXCELLENCE

### PRODUCTS

---

- All Custom Dental Implants
  - ↳ Titanium
  - ↳ Zirconia
- PFM Crowns
  - ↳ Captek (Including Captek Bridges)
- All Ceramic Crowns
  - ↳ Alumina Procera
  - ↳ E-Max
  - ↳ Empress Esthetic
  - ↳ Zirconia
- Porcelain Veneers
- Combination Removable and Fixed Prosthesis
- Essix Retainers
- Sports Guards
- Night Guards
  - ↳ Dual Laminate
  - ↳ Hard & Soft
- Full Metal Crowns
  - ↳ Gold
  - ↳ Silver Palladium
  - ↳ Titanium
- Telio Temporary Crowns

### CERTIFIED LABORATORY IN THE FOLLOWING

---

- Nobel Biocare Implants
- Nobel Biocare CAD/CAM
- Straumann Implants
- Sirona Cerec
- Captek
- Ivoclar Empress & E-max
- Laser Welding



#### **Incisal Edge Dental**

Thomas Kitsos, RDT, Owner and Principal  
3410 Yonge Street,  
Toronto, ON.,  
M4N 2M9

Telephone: 416.489.6533  
Toll free: 1.877.INCISAL  
Fax: 416.489.6541

E-mail: [incisaledge@on.aibn.com](mailto:incisaledge@on.aibn.com)  
Website: [www.incisaledge.ca](http://www.incisaledge.ca)

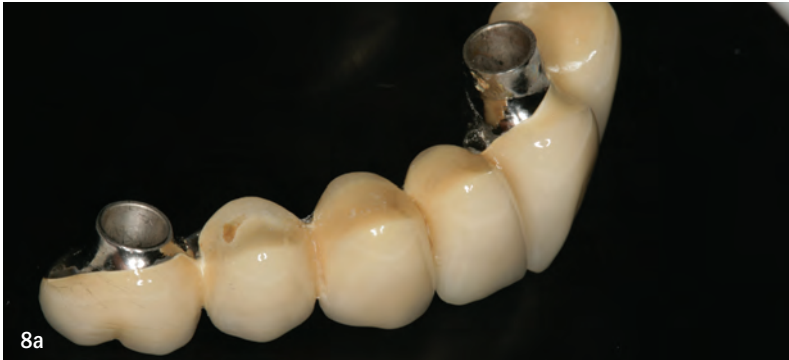

Figure 8a: Close-up of pontic design. With the residual maxillary ridge providing resistance, the soft tissue is directed over the pontic periphery. This not only gives the appearance of a sulcus, but this tissue repositioning also blocks access for oral hygiene implements.

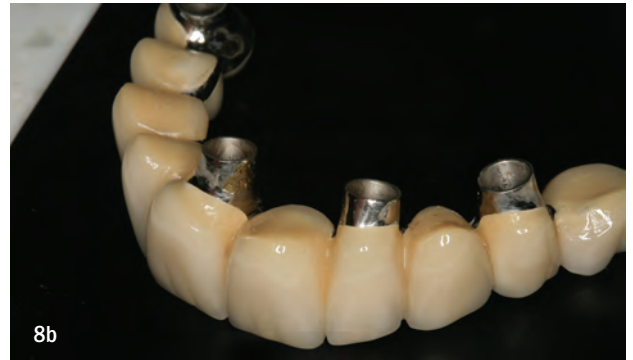

Figure 8b: Animation showing directed compression and desired flow of gingival tissue to interproximal, labial, and palatal areas.

interface, demand as much consideration in design and finishing as the occlusal surface relative to the opposing dentition.

Multiple adjacent pontics – i.e., side-by-side replacements of two or more missing teeth – have an additional requirement, namely that the junction zone between the two pontics be designed to permit the formation of a papilla. The complex contours of the EPP's tissue-contacting surface direct the displaced tissue toward formation of an esthetic papilla at the labial surface. To preserve the newly formed papilla, patients are instructed to use normal brushing methods for oral hygiene and to stimulate the gingival tissue but to avoid passing dental floss underneath the bridge. This regime is also followed at maintenance appointments with dental hygienists to avoid any disruption of the intimate pontic/gingival interface.

This methodology has allowed predictable reproduction of ideal pontic features according to the Rutten criteria.<sup>14</sup> The EPP initially was used for conventional cemented tooth-supported bridges. However, in that application, it was difficult to verify the three-dimensional condition of the soft tissue beneath the pontic over time. Using the EPP in conjunction with dental implants, particularly with screw-retained restorations, facilitates such verification. First, it allows for controlled compression during try-in, enabling a gradual tissue compression and decompression as needed to maintain proper circulation. Second, it enables removal of the bridge at any time after try-in to check the condition of the underlying tissues. The pontic also can be modified by removing and/or adding material as required. This has allowed for more objective validation of the results of using EPPs.

For the past five years, the emphasis has been on porcelain to zirconia restoration with frameworks produced by industrial manufacturing. Zirconia frameworks have provided superior fit, and have the added benefit of more simplified porcelain modification or repair. This technique originally began with porcelain-to-gold screw-retained restorations with good results, and the technique described could be modified for these materials. Because of knife-edged ridges and minimal amounts of attached gingiva, evaluation of suitable techniques for the lower anterior jaw continues.

It should be noted that use of the EPP cannot guarantee ideal results in every situation. When restoring patients who have little compressible tissue, clinicians have less latitude, and there is greater risk of tissue necrosis. It is thus important to assess whether the tissue volume is sufficient to achieve the desired post-compression results. Preparatory work such as a bone contouring, bone augmentation, and/or connective tissue grafts may be advisable to increase the soft-tissue volume.<sup>4,24,25</sup>

## Conclusion

The use of screw-retained, implant-supported, partial- or full-arch restorations that can be removed for direct observation of soft-tissue response has allowed for verification that active engagement of the residual soft-tissue crest through pontic compression can be beneficial. Contour requirements for single and multiple pontic restorations have been identified, and a method to reproduce the critical design elements has been developed. The ability of the Emergence Profile Pontic design to locally

reposition soft tissue that remains vital over time has been demonstrated. Benefits include increases in labial tissue volume and papilla space soft-tissue fill. At the same time, this design simplifies hygiene maintenance, requiring use of a toothbrush only. The Emergence Profile Pontic design can be recommended for maxillary pontics supported by both natural tooth and implant abutments in esthetic areas, with more favorable results being achieved when sufficient residual soft tissue volume is available. Current designs use zirconia frameworks with the apical pontic design computer-milled to precise specifications. Further studies should ideally include histological analysis to determine whether epithelial attachment to biomaterials such as zirconia and porcelain occurs when those materials are incorporated in EPPs. Optimal designs for lower jaws also await investigation.

## References

1. Becker C, Kaldahl W. Current theories of crown contour, margin placement and pontic design. *J Pros Dent* 2005; 93: 112-14, reprinted from *J Prosthet Dent* 1981; 45: 268-77.
2. Behrend DA. The design of multiple pontics. *J Prosthet Dent* 1981; 46(6):634-8.
3. Abrams H, Kopczyk RA, Kaplan AL. Incidence of anterior ridge deformities in partially edentulous patients. *J Prosthet Dent* 1987; 57(2): 191-94.
4. Studer S, Lehner C, Bucher A, Schärer P. Soft tissue correction of a single-tooth pontic space: a comparative quantitative volume assessment. *J Prosthet Dent* 2000; 83(4): 402-11.
5. Kim T, Cascione D, Knezevic A. Simulated tissue using a unique pontic design: A clinical report. *J Prosthet Dent* 2009; 102: 205-10.
6. Nallaswamy D. *Textbook of Prosthodontics*. New Delhi: Jaypee Brothers Publishers 1996: 510.
7. Spear F. The use of implants and ovate pontics in the esthetic zone. *Compendium* 2008; 29(2); 72-4, 76-80; quiz 81, 94.
8. Edelhoff D. A review of esthetic pontic design options. *Quintessence Int* 2002; 33(10): 736-46.
9. Mitrani R, Phillips K, Kois J. An implant-supported, screw-retained, provisional fixed partial denture for pontic site enhancement. *Pract Proced Aesthet Dent* 2005; 17(10): A-F.
10. Dylina, TJ. Contour determination for ovate pontics. *J Prosthetic Dent* 1999; 82(2): 136-42.
11. Zitzmann NU, Marinello C, Berglundh T. The ovate pontic design: a histologic observation in humans. *J Prosthet Dent* 2002; 88(4): 375-80.
12. Al-harbi S. Nonsurgical management of interdental papilla associated with multiple maxillary anterior implants: A clinical report. *J Prosthet Dent* 2005; 93(3): 212-16.
13. Liu C. Use of a modified ovate pontic in areas of ridge defects: a report of two cases. *J Esthet Restor Dent* 2004; 16(5): 273-81; discussion 282-3.
14. Rutten L, Rutten P. *Crown -- Bridge & Implants -- The Art of Harmony*. Fuchstal, Germany: Teamwork Media GmbH; 2006: 230-31.
15. Orsini G, Murgia G, Artese L, Piattelli A, Piccirilli M, Caputi S. Tissue healing under provisional restorations with ovate pontics: a pilot human histological study. *J Prosthet Dent* 2006; 96(4): 252-7.
16. Kerdvongbundit V. Microcirculation and micromorphology of healthy and inflamed gingivae. *Odontology* 2003; 91(1): 19-25.
17. Kocabalkan E, Turgut M. Variation in blood flow of supporting tissue during use of mandibular complete dentures with hard acrylic resin base and soft relining: a preliminary study. *Int J Prosthodont* 2005; 18(3): 210-3.
18. Retzepi M. Comparison of gingival blood flow during healing of simplified papilla preservation and modified Widman flap surgery: a clinical trial using laser Doppler flowmetry. *J Clin Periodontol* 2007; 34(10): 903-11.
19. Holderfield MT, Hughes CC. Crosstalk between vascular endothelial growth factor, notch, and transforming growth factor-beta in vascular morphogenesis. *Circ Res* 2008; 102(6): 637-52.
20. Ohno M. Fluid shear stress induces endothelial transforming growth factor beta-1 transcription and production. Modulation by potassium channel blockade. *J Clin Invest* 1995; 95(3): 1363-9.
21. Patiño-Marín N, Martínez F, Loyola-Rodríguez JP, Tenorio-Govea E, Brito-Orta MD, Rodríguez-Martínez M. A novel procedure for evaluating gingival perfusion status using laser-Doppler flowmetry. *J Clin Periodontol* 2005; 32(3): 231-7.
22. Bouquot JE. Ischemic osteonecrosis under fixed partial denture pontics: radiographic and microscopic features in 38 patients with chronic pain. *J Prosthet Dent* 1999; 81(2): 148-58.
23. Kaidar-Person O. Compression anastomosis: history and clinical considerations. *Am J Surg* 2008; 195(6): 818-26.
24. Calesini G. Edentulous site enhancement: a regenerative approach for the management of edentulous areas. Part 1. Pontic areas. *Int J Periodontics Restorative Dent* 2008; 28(5): 517-23.
25. Azzi R, Etienne D, Takei H, Fenech P. Surgical thickening of the existing gingiva and reconstruction of interdental papillae around implant-supported restorations *Int J Periodontics Restor Dent* 2002; 22(1): 71-7.

Corresponding author: Dr. Yvan Fortin - yvan.fortin@gmail.com.

"This article originally appeared in the *Journal of Implant & Advanced Clinical Dentistry (JIAD)*, V5N9, September 2013".



**accelerate your implant practice . . .**



Implant systems that we help drive

BioHorizons / Biomet 3i / camlog / DentsplyImplants / MDI  
MiS / NobelBiocare / straumann / Sybron / Zimmer

**TEST DRIVE**

**Shaw implant restorative expertise today!**



Centres of Excellence

London  
519-453-7352

Toronto  
416-977-0700  
800-387-2969

Cornwall  
613-933-0056

Kitchener  
519-742-9002

Brampton  
905-450-0033

Richmond Hill  
905-883-3980

Kingston  
613-548-7854

Ottawa  
613-232-5303

[www.shawlabgroup.com](http://www.shawlabgroup.com)



# Snoring and sleep apnea: what is the role of the general dentist in practical terms?



Dr David Côté, DMD

## Abstract

Formerly unheard of within the field of dentistry, the treatment of sleep apnea and snoring is increasingly seen within the context of our practice as general dentists. In essence, not a week goes by without patients asking if we can help them with snoring issues. Some ask for our opinions on the different devices available on the market or over the Internet. Some dentists may feel ill-prepared to answer such questions. The objective of this article is to familiarise practitioners with snoring and sleep apnea issues and to introduce a management process. We will also explore different treatment methods.



## Etiology and detection of sleep apnea

Snoring is a noise, of varying intensity, which is the result of the vibrations of the pharynx tissue of the soft palate and the uvula, where air flows. Contrary to what has been stated up until now, the tissue loses tone during sleep and the horizontal position assumed when resting acts so that gravity pushes the tongue and other tissue toward the back of the oral cavity. Where breathing is interrupted, this is referred to as sleep apnea. According to the APSS<sup>1</sup> definition, sleep apnea refers to a disruption of breathing lasting 10 seconds, with visible effort of the inspiration muscles, accompanied by a low level of oxygen in the blood. Central sleep apnea is used to refer to a situation where

breathing stops, and where the inspiration muscles demonstrate no effort to re-start breathing.

There are many questionnaires and clinical guidelines used to identify the presence of sleep apnea in patients. Within my practice, we use the "Epworth Sleepiness Scale" questionnaire presented in figure 2. However, at present, only polysomnography tests (sleep tests) are recognised in terms of diagnosing this condition. To determine the severity of the case, an average of the breathing issues, per hour, is recorded. It is normal to observe up to 5 instances of breathing interruptions an hour, a mild sleep apnoea condition is defined as between 5 and 15 episodes, a moderate case, between 15 and 30 episodes, and more

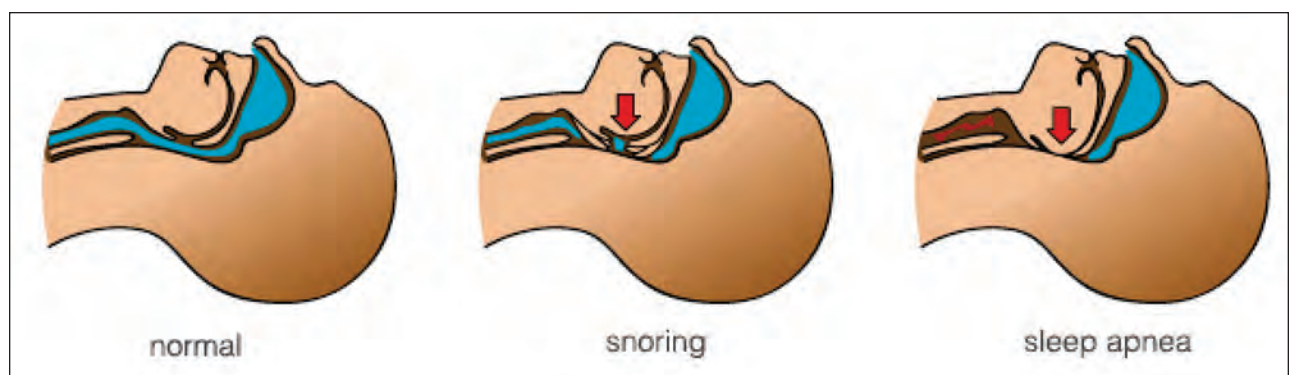


Fig. 1 Diagram illustrating the progressive obstruction of the oropharynx during sleep apnea <sup>2</sup>

than 30 episodes per hour may be recorded in severe cases<sup>1</sup>.

The role of the dentist is to identify, among patients, those who could benefit from treatment and to refer them, where possible, for a more in-depth medical examination. Dental teams are perfect for this purpose: our surgeries see more than 50% of the population, twice a year. We are also able to correctly assess the anatomic structures that feature in the pathology. Multiple resources are available to care for these patients. Numerous hospitals have sleep laboratories and private companies offer sleep test services within the majority of the regions across the country. It is very important to specify that most medical

consultants involved in diagnosing sleep apnea are not very familiar with dental devices and related instructions. It is therefore recommended that those dentists wishing to, be involved within this practice, overseeing management of such patients, alongside the medical entity in charge of the diagnosis.

### Prevalence and consequences of sleep apnea

According to Canadian data published in 2009, 3% of the population aged over 18, has been diagnosed with sleep apnea. This increases to 5%, among adults over 45. According to this same study, among those who have not been diagnosed with sleep

### Epworth Sleepiness Scale

#### JohEpworth Sleepiness Scale

Johns MW (Sleep 1991; 14:540-5) "A new method for measuring day time sleepiness: The Epworth Sleepiness Scale. Sleep".

#### Sleepiness is the tendency to fall asleep where not stimulated.

(Nb. This feeling is completely different from the feeling of tiredness which forces people to rest).

The following questionnaire which aims to assess subjective sleepiness, is founded on the objective results gathered from recording sleep.

Forename: ..... Surname: ..... Date of birth:.....

Date of test:..... Snoring? ..... yes ..... No.....

#### Do you doze off or fall asleep (during the day) in the following situations:

Even if you have not recently found yourself in such a situation, try to imagine how you would react and what the likelihood of you dozing off would be.

score **0**: where **impossible**. "I never doze off": **no** chance,

score **1**: where it is **possible**. "There is a slim chance": **slim** chance,

score **2**: where **probable**. "I may doze off": **average** chance,

score **3**: where **definite**. "I doze off every time": **high** chance.

- Whilst reading a document.....0 1 2 3
- In front of the TV or at the cinema .....0 1 2 3
- Seated in a public place (waiting room, theatre, classes, meetings ...).....0 1 2 3
- Travelling, for at least half an hour without disruption, in a car or form of public transport (train, bus, plane, tube...).....0 1 2 3
- When lying down for a rest, where circumstances allow.....0 1 2 3
- Seated during a conversation (or on the telephone) speaking to a loved one .....0 1 2 3
- Calmly seated at the table at the end of a meal not having consumed alcohol.....0 1 2 3
- Behind the wheel of a stationary car for a few moments during a traffic jam.....0 1 2 3

#### Total (from 0 to 24):

- **Below 8: you do not have a sleep issue.**

- **From 9 to 14: you have a sleep issue, review your habits.**

- **If the total exceeds 15: you show signs of excessive**

**daily sleepiness. Make an appointment to see your doctor to establish whether you have a sleep disorder. Otherwise, think about reviewing your habits.**

NB. This questionnaire helps measure your general sleepiness level, it is not a diagnosis. Take the questionnaire to your doctor and discuss the causes and consequences that this disorder has on your life.

<http://www.sommeil-mg.net> (copy left, the original source must be mentioned)

Figure 2: the Epworth Sleepiness Scale questionnaire <sup>3</sup>

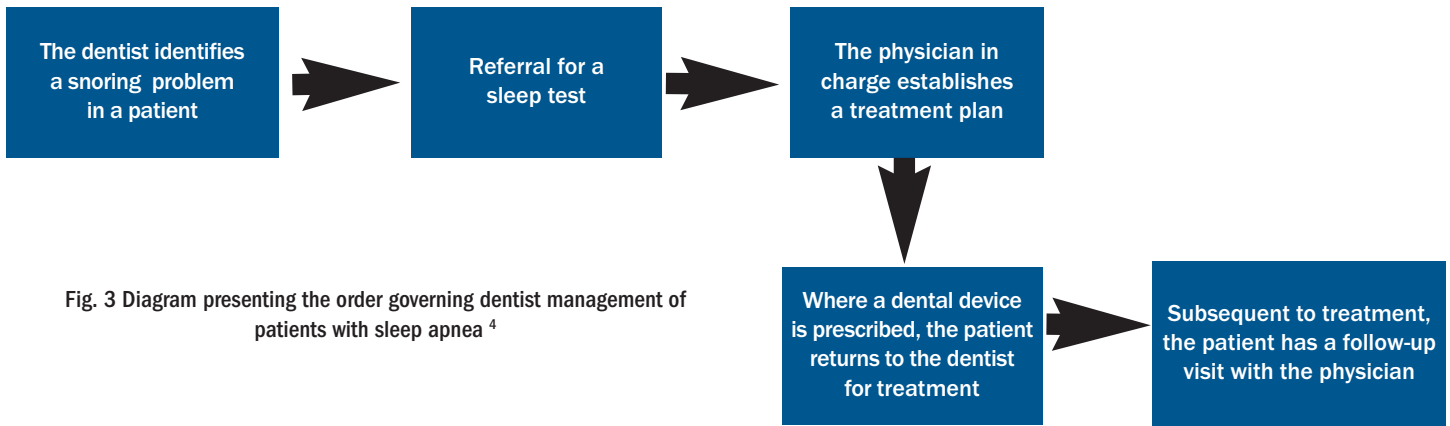


Fig. 3 Diagram presenting the order governing dentist management of patients with sleep apnea <sup>4</sup>

apnea, 26% present symptoms and risk factors of developing sleep apnea disorders.<sup>3</sup> Men are at greater risk than women at an approximate ratio of 3 to 1.<sup>5</sup>

Some of the disorders associated with sleep apnea are high blood pressure, type 2 diabetes, obesity, depression, loss of libido, concentration issues and memory loss.<sup>6</sup> Some recent articles also make a connection between sleep apnea and Alzheimer's disease.<sup>7</sup> Other statistics present the rate of car accidents as 15 times greater than in a standard population.<sup>8</sup> In summary, sleep apnea significantly reduces life expectation and patient quality of life. However, owing to the fact that the condition develops slowly, the patient rarely notices the problem.

Bearing in mind the severe consequences of sleep apnea on health, the numerous associated conditions and the potential side-effects of available treatments, it is essential that accurate diagnosis is provided before treatment is planned for the patient. It is vital, from a medical point of view, to have an accurate clinical assessment of the patient in order to find the most suitable treatment for the latter.

Upon reading this article, all prudent dentists will acknowledge that the diagnosis of this condition is not within the scope of their practice. Sleep apnea and snoring are medical conditions. However, some cases, where prescribed, may be treated by

dentists. It has been proven that dental devices significantly reduce sleep apnea episodes over a long-term period and have an excellent rate of success.<sup>9</sup>

### Treatment devices

The most popular treatment for sleep apnea is CPAP or Continuous Positive Airway Pressure. This device, which involves air flow and a face mask, operates by blowing pressurized air into airways, unblocking them and enabling patients to breathe. CPAP is a very effective treatment, however its main drawback is its low level of compliance with the treatment.<sup>11</sup> According to the recommendations of the Canadian Sleep Society, CPAP is specifically advised, primarily, in cases of severe or moderate sleep apnea or those accompanied with marked symptoms.

Where purchased from a breathing device company, the cost of a CPAP may vary, and necessitate many thousands of dollars, all dependent on the type of machine selected and the accessories included. In Québec, the RAMQ (government health insurance) does not cover the cost of these devices, which are generally well covered by private insurance policies.

Dental devices, primarily use the principle of mandibular advancement. Other devices that hold the tongue back are also available, but they are not commonly used. By securing the mandible in a forward position, it is possible to re-configure the upper airways, facilitating air flow and preventing episodes of obstruction to breathing. Dental devices are particularly recommended for cases of snoring, where sleep apnea is mild or moderate, without too many symptoms. It can also be used in cases of severe sleep apnea, where CPAP has failed.

There is no fixed price scale for the treatment and monitoring of the devices. But after discussions with fellow practitioners, the cost of these services represents several thousands of dollars. Reimbursement from insurance companies may be problematic as most operate on a case-by-case basis.

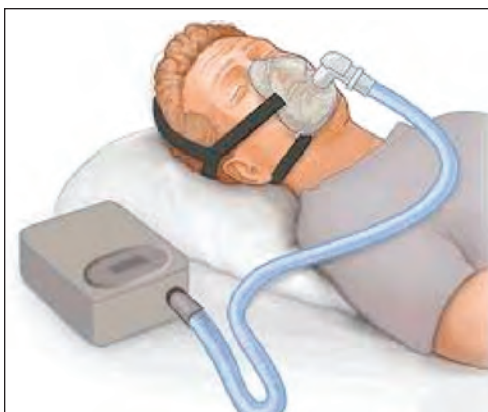

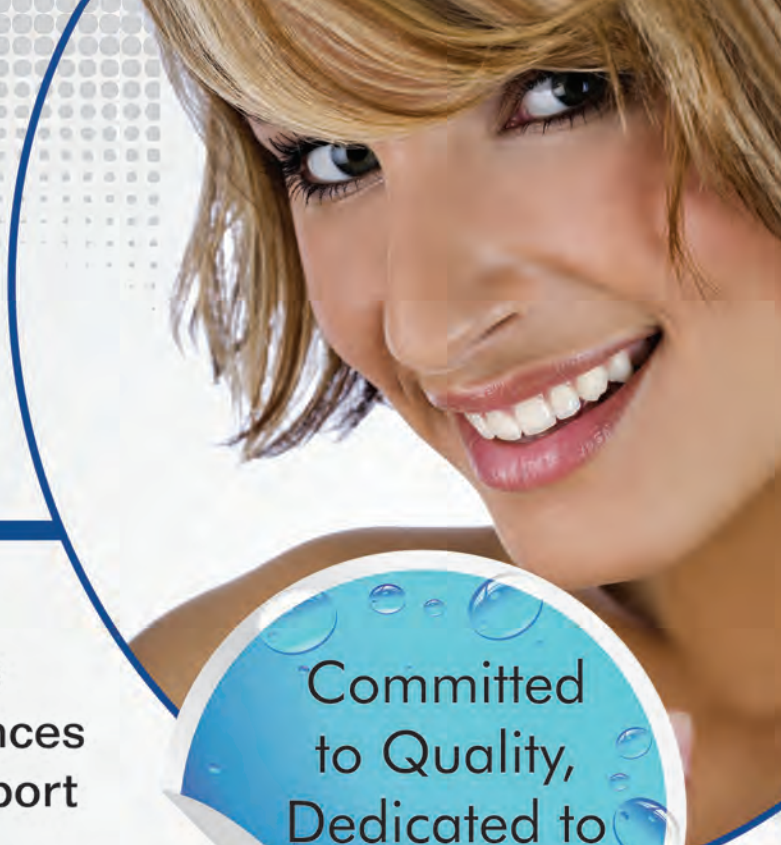Fig 4: Illustration of the Continuous Positive Airway Pressure (CPAP)<sup>10</sup>





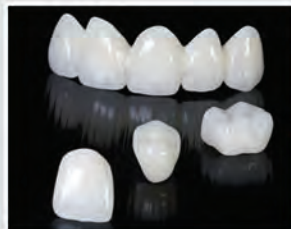# Orthodont<sup>®</sup>

## Your Full Service Dental Laboratory



Providing general dentists and orthodontists with leading-edge custom restorations and appliances along with expert technical support from start to finish.

Committed  
to Quality,  
Dedicated to  
Service!



## Crowns & Bridges

NobelProcera<sup>™</sup> | IPS e.max<sup>®</sup> | Custom Shading & Staining | Zirconia & Full Contour Zirconia | Implants



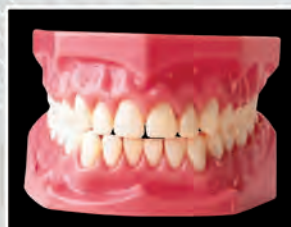## Orthodontics

Twin Block | Series 2000<sup>®</sup> | Herbst | Schwartz | Sagittal | Mara | Super Screw  
Habit Breakers | Splints | Orthotics | Positioners | Rapid Palatal Expanders | Invisible Aligners | A.L.F.



## Snoring & Sleep Apnea

Narval CC<sup>™</sup> | SomnoDent<sup>®</sup> MAS | SILENT NITE<sup>®</sup> | TAP<sup>®</sup> | OASYS | SILENCER<sup>®</sup> | EMA<sup>®</sup>



## Dentures

Valplasi<sup>®</sup> | IVOCAP<sup>®</sup> & Success Injection System<sup>™</sup> | Lucitone 199<sup>®</sup> | DURACETAL<sup>®</sup> Clasps  
ZEST<sup>®</sup> Anchor Attachments | Vita | Bioform<sup>®</sup> | Bioblend<sup>®</sup> | Portrait<sup>®</sup> | Vivodent | Kenson<sup>®</sup> | Classic<sup>®</sup>

Call **1-800-267-8463** today! • [www.orthodont.ca](http://www.orthodont.ca)

A recent study comparing CPAP and dental devices applied to a group of severe cases, has concluded that the 2 alternative treatments are generally similar in terms of effectiveness: although the CPAP is more efficient than the dental devices, the very fact that the patient uses the dental devices for a great number of hours than the CPAP, means, that overall, the 2 options are comparable in terms of success.<sup>12</sup>

What about the dental devices available on the market? They have been available for twenty or so years. Their use is limited owing to the fact that their effectiveness and ability to adapt to their use is restricted as they are not made to measure, which greatly impacts on patient comfort. Such devices often discourage patients who would otherwise make excellent candidates for made-to-measure dental devices, as the generic ones are too uncomfortable or inadequate. Scientific literature speaks of efficacy and compliance that are 50% lower than with made-to-measure devices.<sup>13</sup>

Whereas health professionals are subjected to strict practice standards, with the aim of optimizing success rates, dental devices sold on the market are not subject to any regulations. They provide patients with the illusion that it is possible to self-diagnose, select the suitable treatment and manage the potential side-effects themselves. This approach does not protect the public, which is at great risk. The clinical case below illustrates this point.

### Clinical Case

A 49 year old man complains of snoring problems. He feels very tired and is finding it hard to concentrate throughout the day.

His dental condition has been stable for many years with a Class I occlusion. His family doctor has never referred him for a sleep study. He found many sites online, where, for a small cost, he could purchase dental devices to treat his snoring.

At first, the treatment seemed productive, however, the snoring and fatigue returned within a month or two. The patient subsequently experienced pain of the temporomandibular joint and of his teeth, and found chewing food difficult. During a routine examination, his regular dentist noted that he had an open occlusion and that contact was only made between teeth 27 and 37. A summary analysis showed that the patient had a Class III skeletal occlusion. If one tried to articulate the models, the intercuspitation was adequate. However, despite conservative treatments involving physiotherapy and the use of a mouth guard, it was not possible to reinstate a satisfactory occlusion.

The patient was referred to orthodontics, where an orthognathic surgery approach was considered to re-establish a satisfactory occlusion and eliminate all sleep apnea issues.<sup>14</sup> Alongside all the treatments carried out on the occlusion, the patient was also referred to evaluate the genuine scope of his snoring problem. The moderate sleep apnea diagnosis, with symptoms, was confirmed. The specialist physician prescribed a CPAP which was well tolerated by the patient.

To summarize, what initially appeared to be a case of snoring, proved to be a case of sleep apnea, with potential damages to the patient's health. The patient's self diagnosis, where he didn't know the nature of his problem, his use of inappropriate devices, in addition to the lack of monitoring, resulted in the patient suffering extremely costly complications, both financially and biologically. They could have all been avoided if the standard treatment protocol had been adopted. Moreover, given the complications the patient experienced with his over-the-counter purchase, he would be skeptical about using any made-to-measure dental device to treat his sleep apnea in the future. I am convinced that if, right from the start, suitable dental devices had been selected and that monitoring had been correctly provided, the patient would not have suffered any of these complications. In an attempt to save a few thousand dollars, the patient is facing complications which will cost five times more than he hoped to save.

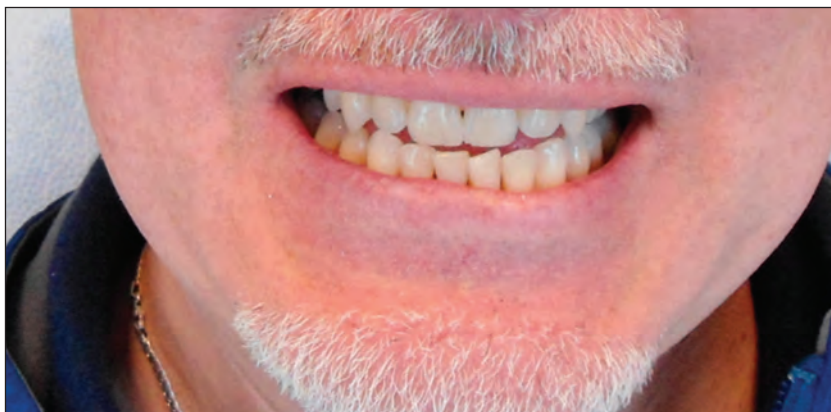

Fig. 5: Acquired Class III bite showing mandibular advancement after wearing a dental device available on the market

For better dentistry

**DENTSPLY**  
CANADA

NO MORE CORD. NO MORE PASTE.

**DON'T LET  
CORD RUN WILD  
ANYMORE.**

IMPRESSION MAKING WILL  
NEVER BE THE SAME.

 **AquasilUltra**  
CORDLESS

TISSUE MANAGING IMPRESSION SYSTEM

[www.aquasilultracordless.com](http://www.aquasilultracordless.com)



See it to believe it

at the ODA Tradeshow  
Dentsply Booth# 1503  
May 8-10, 2014 (Toronto, ON)

BOOK AN IN-OFFICE  
DEMO TODAY!

1.877.393.3687

**Introducing the first retractionless  
Tissue Managing Impression System.**

Aquasil Ultra Cordless is the first and only Tissue Managing Impression System that eliminates the need to retract tissue. No need for cord. No need for paste. Just an easy, one-step system that places high tear strength wash material precisely in the sulcus within seconds for a stress-free experience that creates incredibly accurate marginal detail. It's the first true breakthrough in impression making in decades.



[www.dentsply.ca](http://www.dentsply.ca) | 1.877.393.3687

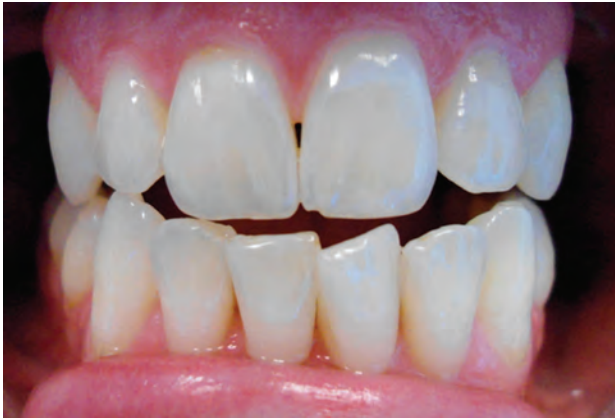

Fig. 6 a): absence of anterior contacts;

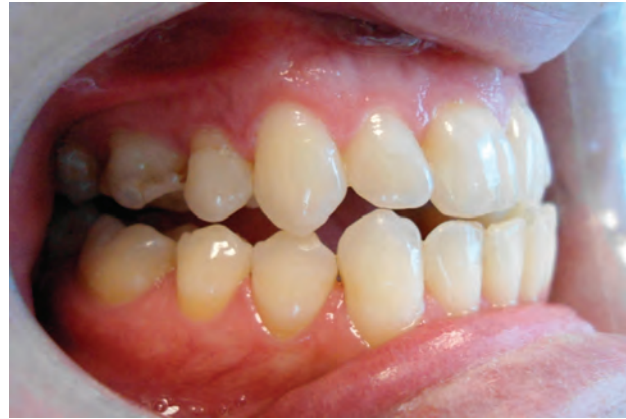

Fig. 6 b): absence of posterior contacts

In our second article on sleep apnea and snoring, we will speak in more detail of the different types of dental devices available, and used by dentists, their side-effects and the principles governing management of any complications.

### About the author

Dr David Côté obtained his Doctorate in Dental Medicine from U de Montréal in 1996. He established a private practice in Gatineau. Ever since, Dr Côté has been interested in the treatment of snoring and sleep apnea using dental devices.

Dr Côté is a member of the American Academy of Dental Sleep Medicine, a representative of the American Board of Dental Sleep Medicine and founding member of the dental section of the Canadian Sleep Society. He works, notably, in collaboration with the Outaouais Neuro Clinic and Ottawa Hospital, overseeing the treatment of sleep apnea.

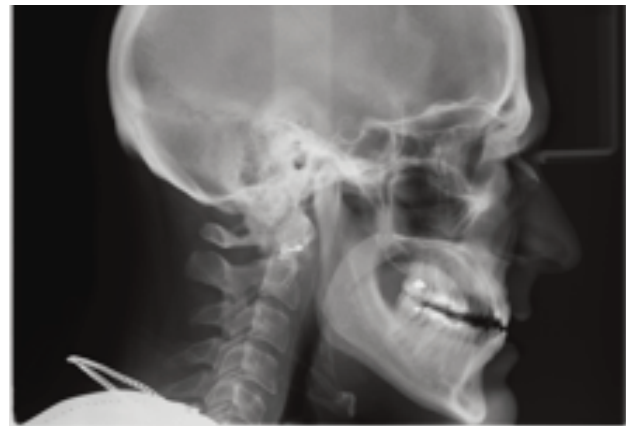

Fig.7: Cephalogram illustrating the condyle's anterior displacement and the generalized open bite occlusion

### Bibliography

- 1) Fleetham J., Ayas N., Bradley d., Ferguson K., Fitzpatrick M., George C., Hanley P., Hill F., Kimoff J., Kryger M., Morrison D., Series F., Tsai W., Directives de la Société Canadienne de Thracologie: Diagnostic et traitement des troubles respiratoires du sommeil de l'adulte (Directives of the Canadian Thracology Society: Diagnosis and treatment of sleep respiratory conditions in adults). *Can Resp J* 2006; 13(7) :387-392
- 2) www.orthoapnea.com
- 3) www.sommeil-mg.net
- 4) Gauthier L., Almeida F., Arcache JP., Ashton McGregor C., Côté D., Driver HS., Ferguson KA., Lavigne GJ., Martin P., Masse JF., Morisson F., Pancer J., Samuels CH., Schachter M., Series F., Sullivan GE., Position paper by Canadian Sleep medicine professionals on the role of different health care professionals in managing obstructive sleep apnoea with oral appliances. *Can Respir J* 2012 Sept-Oct; 19(5):307-9
- 5) Points saillants de l'Enquête sur la santé dans les collectivités canadiennes de 2009-Réponses rapides sur l'apnée du sommeil, (Prominent points of the 2009 Study on the health of Canadian populations - Rapid responses on sleep apnoea) Publication of the Agence de la santé publique du Canada (Public Health Agency of Canada), 2009
- 6) Marshall NS., Wong KK., Liu PY., Cullen SR., Knuiman MW., Grunstein RR, Sleep apnoea as an independent risk factor for all-cause mortality: the Brusselton Health study, *Sleep* 2008 Aug; 31 (8) 1079-85
- 7) Sjoström C., Lindberg E., Elmasry A., Hagg A., Svardsudd A., Janson C., Prevalence of sleep apnoea and snoring in hypertensive men: a population based study, *Thorax* 2002 Jul; 57(7):602-7
- 8) Buratti L., Vittichi G., Falsetti L., Cagnetti C., Luzzi S., Bartolini M., Provinciali L., Silvestrini M., Vascular impairment in Alzheimer's disease : the role of obstructive sleep apnoea. *J. Alzheimers dis.* 2014 Jan 1; 38(2) 445-53
- 9) Horstmann S., Hess CW., Bassetti C., Gugger M., Mathis J., Sleepiness-related accidents in sleep apnoea patients, *Sleep* 2000 May 1;23(3):383-9
- 10) [http://en.wikipedia.org/wiki/Positive\\_airway\\_pressure](http://en.wikipedia.org/wiki/Positive_airway_pressure)
- 11) Gauthier L., Laberge M., Beaudry M., Laforte M., Rompré PH., Lavigne GJ., Mandibular advancement appliance remain effective in lowering respiratory disturbance index for 2.5-4.5 years., *Sleep med.* 2011 Oct; 12 (9):844-9
- 12) Boyaci H., Gakar K., Bans SA., Basyiqit I., Yildiz F., Positive airway pressure device compliance of the patients with obstructive sleep apnea syndrome., *Adv Clin Exp Med.* 2013 Sept-Oct;22(6):809-15
- 13) Sutherland K., Vanderveken OM., Tsuda H., Marklund M., Gagnadoux F., Kushida CA., Cistulli PA. Oral appliance treatment for obstructive sleep apnoea: an update. *J Clin Sleep Med* 2014 Feb 15; 10(2): 215-227
- 14) Vanderveken OM., Devolder A., Marklund M., Boudewyns AN., Braem MJ., Okkerse W., Verbraeken JA., Franklin KA., De Backer WA., Van de Heyning PH., Comparison of a custom made and a thermoplastic oral appliance for the treatment of mild sleep apnoea. *Am J Crit Care Med* 2008 Jul 15;178(2): 197-202
- 15) Li KK., Maxillomandibular advancement for obstructive sleep apnoea. *J Oral Maxillofac surg* 2011 Mar; 69(3):687-94.

# Periodontics for the GP: A Practical Approach

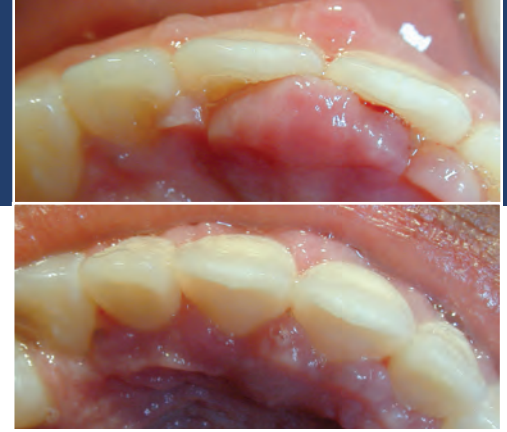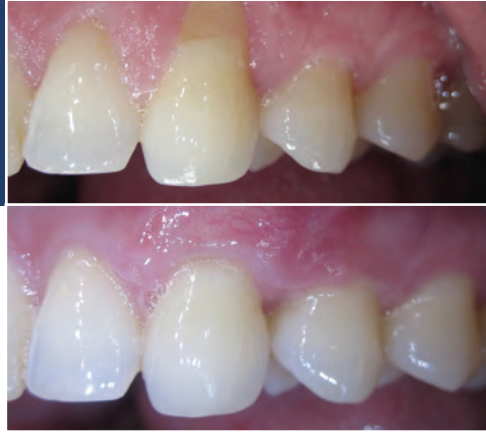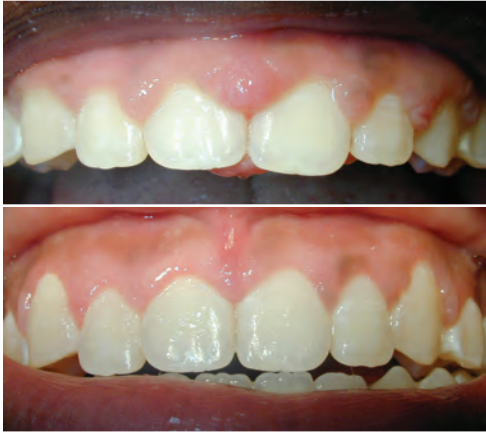Dr. Edy Braun, Hon. BSc, DDS, Cert. Perio, FRCDC(C)

## A Three Day Hands-on Seminar

Date: October 31<sup>st</sup> - November 2<sup>nd</sup>, \$2,200 + HST

Location: Springhill Suites by Marriott Toronto/Vaughan  
612 Applewood Crescent, Vaughan, On L4H 0R2

Save Your  
Placement  
NOW!



### Day 1: Periodontal Disease

1. disease etiology overview, monitoring and charting, hygiene surveillance
2. radiographic interpretation, treatment planning, proper sequencing
3. non-surgical options, chemotherapeutics, lasers
4. resective surgical techniques
  - a) open flap debridement - flap curettage, distal wedge
  - b) crown-lengthening (esthetic and functional)

### Day 2: Regenerative surgical techniques

1. Soft-tissue grafting
  - a) free gingival graft
  - b) connective tissue graft
  - c) frenectomy
2. Hard-tissue grafting
  - a) guided tissue regeneration (osseous defects around teeth)
  - b) guided bone regeneration (for implant or pontic site development)

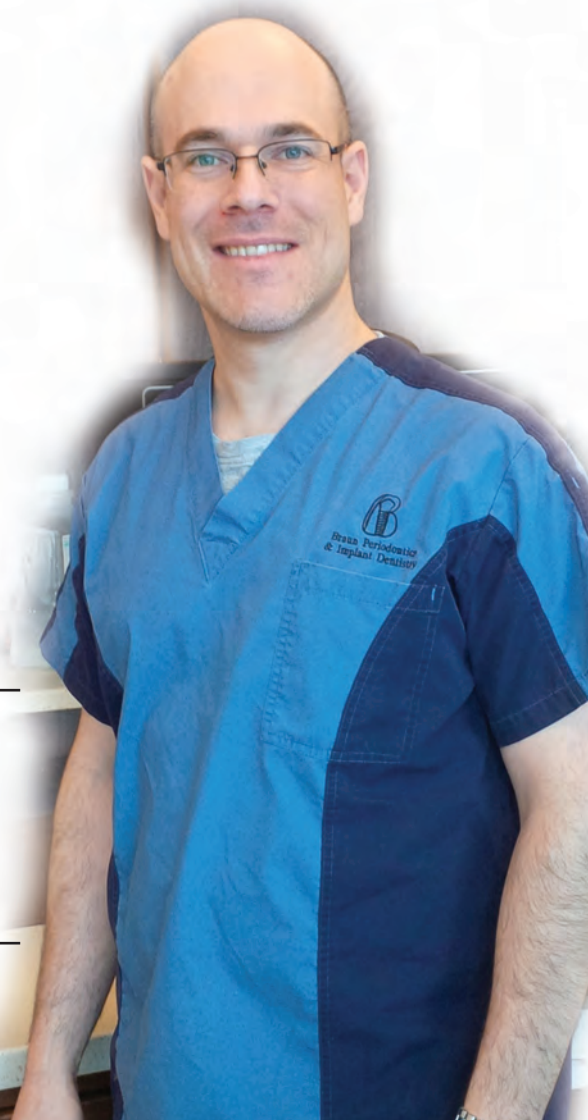### Day 3: Hands-On Surgery and Suturing

1. practice techniques learned in the first 2 days....
2. open flap debridement surgery, continuous sling sutures
3. crown-lengthening surgery, vertical external mattress sutures
4. ridge augmentation surgery/implant bone graft, split-thickness flap
5. free gingival grafting and associated suturing
6. connective tissue grafting and associated suturing

### To register contact:

Palmeri Publishing at 905.489.1970 or  
Email: [seminars@palmeripublishing.com](mailto:seminars@palmeripublishing.com)  
[events@palmeripublishing.com](mailto:events@palmeripublishing.com)


► 21 credits for seminar attendance



Approved PACE Program Provider FAGD/MAGD  
Credit Approval does not imply acceptance by a  
state or provincial board of dentistry or AGD  
endorsement 9/1/2013 to 8/31/2015 .  
Provider ID# 355116



Palmeri Publishing Inc.  
Phone : 905. 489.1970  
Fax Orders: 905. 489.1971



# Ronflement et apnée du sommeil: quel est le rôle du dentiste généraliste dans le processus de prise en charge en pratique?



Dr David Côté, DMD

## Résumé

Autrefois inconnu dans le domaine dentaire, le traitement de l'apnée du sommeil et du ronflement a de plus en plus d'impact dans nos pratiques de généralistes. En effet, il ne se passe pas une semaine sans qu'un patient nous demande comment nous pouvons l'aider avec ses troubles de ronflement. D'autres nous demandent notre opinion sur les différents appareils disponibles en vente libre ou sur internet. Il se peut que le dentiste se sente mal outillé pour répondre à ces questions. Le but de l'article qui suit est de familiariser le praticien avec les troubles de ronflement et d'apnée du sommeil et de présenter le processus de prise en charge de la condition. Les différentes modalités de traitement ainsi que leurs indications seront explorées.



## Étiologie et dépistage de l'apnée du sommeil

Le ronflement est un bruit, d'intensité variable, qui résulte de la vibration des tissus du pharynx, du palais mou et de la luette lors du passage de l'air. Contrairement à ce qu'on observe le jour, ces tissus perdent du tonus lors du sommeil et la position horizontale durant le repos fait en sorte que la gravité repousse la langue et les autres tissus vers le fond de la cavité buccale. On parle d'apnée du sommeil lorsqu'il y a une interruption de la respiration. Selon la définition de l'APSS<sup>1</sup> on parle d'apnée obstructive du sommeil lorsqu'on enregistre une interruption de la respiration de 10 secondes, tout en observant des efforts au niveau des muscles inspiratoires. Le tout est accompagné d'une baisse du taux d'oxygène dans le sang. On parle d'apnée centrale lorsqu'on remarque un arrêt respiratoire, sans que les muscles inspiratoires ne fassent d'effort pour que la respiration s'effectue.

Il existe plusieurs questionnaires et indices cliniques pouvant nous mener à soupçonner la présence d'apnée du sommeil chez un patient. Le questionnaire utilisé dans ma pratique est 'L'Échelle de Somnolence d'Epworth', présenté à la figure 2. Toutefois, présentement seul des tests de polysomnographie (tests du sommeil) sont reconnus pour diagnostiquer cette condition. Pour déterminer la sévérité de la maladie, on compile la moyenne d'évènements respiratoires, à l'heure. Il est normal d'observer jusqu'à 5 arrêts respiratoires à l'heure, un cas léger d'apnée du sommeil se caractérise par une moyenne d'évènements se situant entre 5 et 15 évènements, un cas modéré entre 15 et 30 et on verra des indices se situant à plus de 30 évènements à l'heure dans les cas sévères.<sup>1</sup>

Le rôle du dentiste est de dépister, parmi ses patients, ceux qui pourraient bénéficier de traitement et de les référer, le cas échéant, pour une évaluation médicale plus approfondie. L'équipe dentaire est parfaite pour ce rôle:

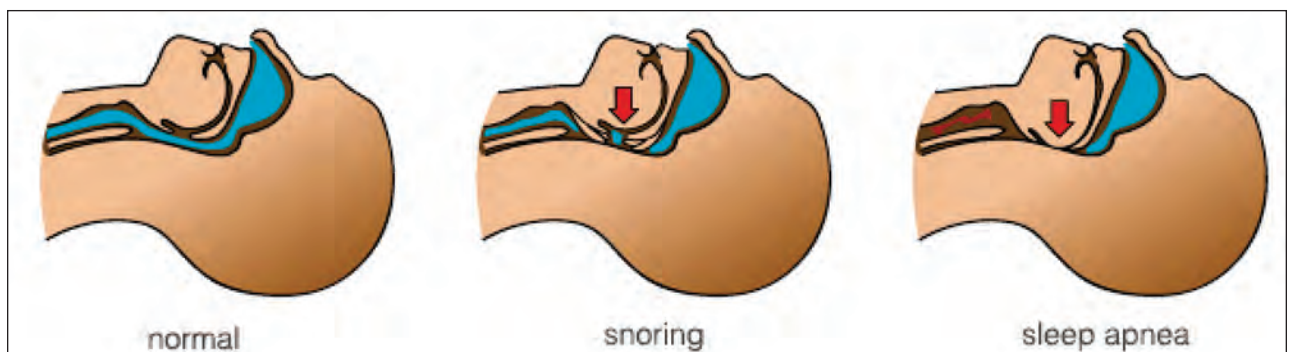


Fig. 1 Schémas illustrant l'obstruction progressive de l'oro-pharynx menant à l'apnée du sommeil <sup>2</sup>

nos bureaux voient plus de 50% de la population, 2 fois par année. Nous sommes aussi en mesure de bien évaluer les structures anatomiques impliquées dans la pathologie. Plusieurs ressources sont disponibles pour prendre en charge ces patients. Nombreux hôpitaux disposent de laboratoires du sommeil et des compagnies privées offrent des services de tests du sommeil, dans la majorité des régions du pays. Il est très important de préciser que la plupart des intervenants médicaux impliqués dans le diagnostic de l'apnée du sommeil sont peu familiers avec les appareils dentaires et leurs indications. Il est recommandé que le dentiste désirant s'impliquer dans ce champ de pratique s'entende sur un protocole de prise en charge de patients avec l'entité médicale qui sera en charge du diagnostic.

### Prévalence et séquelles de l'apnée du sommeil

Selon des données canadiennes publiées en 2009, 3% de la population de plus de 18 ans ont reçu un diagnostic d'apnée du sommeil. Chez les gens de plus de 45 ans, cette proportion passe à 5%. Toujours selon la même enquête, parmi la population adulte n'ayant pas été diagnostiquée, 26% d'entre eux présentent des symptômes et des facteurs de risques de développer des troubles d'apnée du sommeil.<sup>3</sup> Les hommes seraient atteints dans une plus grande proportion que les femmes selon un ratio d'environ 3 pour 1.<sup>5</sup>

#### Échelle de somnolence d'Epworth

Johns MW (Sleep 1991; 14:540-5) «A new method for measuring day time sleepiness : The Epworth Sleepiness Scale.Sleep».

**La somnolence est la propension plus ou moins irrésistible à s'endormir si l'on n'est pas stimulé.**

(Nb. Ce sentiment est très distinct de la sensation de fatigue qui parfois oblige à se reposer).

Le questionnaire suivant, qui sert à évaluer la somnolence subjective, est corrélé avec les résultats objectifs recueillis par les enregistrements du sommeil.

Prénom : ..... Nom : ..... Date de naissance:.....

Date du test :..... Ronflement? ..... oui ..... Non.....

**Vous arrive-t-il de somnoler ou de vous endormir (dans la journée) dans les situations suivantes:**

Même si vous ne vous êtes pas trouvé récemment dans l'une de ces situations, essayez d'imaginer comment vous réagiriez et quelles seraient vos chances d'assoupissement.

notez **0** : si c'est exclu. «Il ne m'arrive jamais de somnoler: aucune chance,

notez **1** : si ce n'est pas impossible. «Il y a un petit risque»: faible chance,

notez **2** : si c'est probable. «Il pourrait m'arriver de somnoler»: chance moyenne,

notez **3** : si c'est systématique. «Je somnolerais à chaque fois»: forte chance.

- Pendant que vous êtes occupé à lire un document ..... 0 1 2 3
- Devant la télévision ou au cinéma..... 0 1 2 3
- Assis inactif dans un lieu public (salle d'attente, théâtre, cours, congrès ...) ..... 0 1 2 3
- Passager, depuis au moins une heure sans interruption, d'une voiture ou d'un transport en commun (train, bus, avion, métro ...) ..... 0 1 2 3
- Allongé pour une sieste, lorsque les circonstances le permettent..... 0 1 2 3
- En position assise au cours d'une conversation (ou au téléphone) avec un proche ..... 0 1 2 3
- Tranquillement assis à table à la fin d'un repas sans alcool..... 0 1 2 3
- Au volant d'une voiture immobilisée depuis quelques minutes dans un embouteillage ..... 0 1 2 3

**Total ( de 0 à 24):**

- **En dessous de 8: vous n'avez pas de dette de sommeil.**

- **De 9 à 14: vous avez un déficit de sommeil, revoyez vos habitudes.**

- **Si le total est supérieur à 15: vous présentez des signes de somnolence**

**diurne excessive. Consultez votre médecin pour déterminer si vous êtes atteint d'un trouble du sommeil. Si non, pensez à changer vos habitudes.**

NB. Ce questionnaire aide à mesurer votre niveau général de somnolence, il n'établit pas un diagnostic. Apportez-le à votre médecin pour discuter avec lui des causes et des conséquences de ce handicap dans votre vie.

<http://www.sommeil-mg.net> (copyleft sous réserve de mentionner la source)

Figure 2 : le questionnaire de l'échelle de somnolence d'Epworth <sup>3</sup>

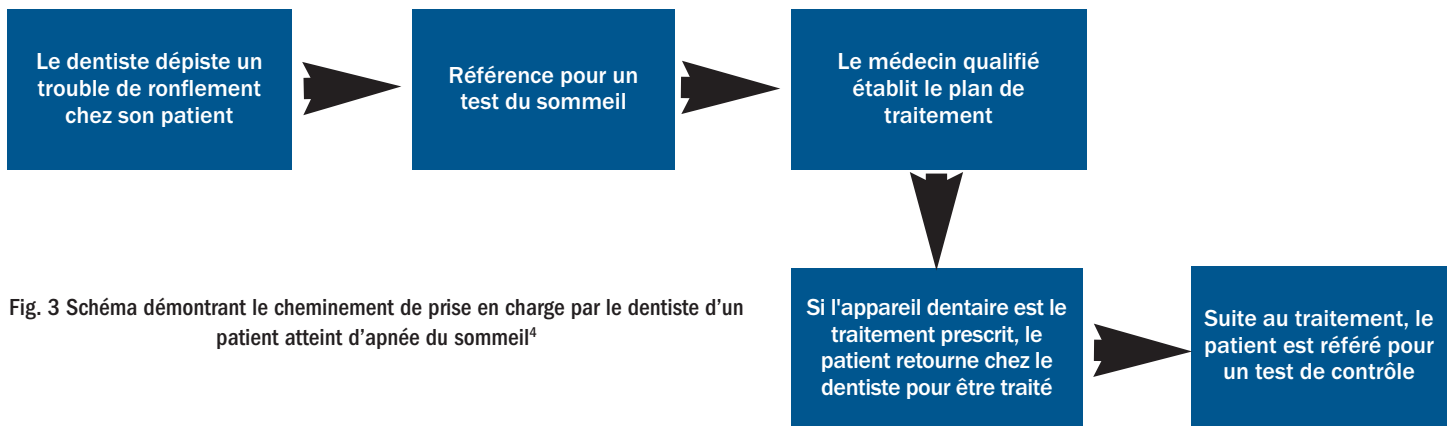


Fig. 3 Schéma démontrant le cheminement de prise en charge par le dentiste d'un patient atteint d'apnée du sommeil<sup>4</sup>

Parmi les co-morbidités associées à l'apnée du sommeil, on note principalement l'hypertension artérielle, le diabète type 2, l'obésité, la dépression, la perte de libido, des troubles de concentration et des pertes de mémoire.<sup>6</sup> Certains articles récents font même un lien entre la présence d'apnée du sommeil et la maladie d'Alzheimer.<sup>7</sup> D'autres statistiques démontrent un taux d'accident de voiture jusqu'à 15 fois plus élevé qu'une population normale.<sup>8</sup> En résumé, l'apnée du sommeil diminue significativement l'espérance de vie et la qualité de vie du patient. Toutefois, dû au fait que la condition se développe lentement, le patient ne réalisera que très rarement l'étendue de son problème.

Compte tenu des séquelles sévères sur la santé provenant de l'apnée du sommeil, des nombreuses co-morbidités associées à cette condition et aux effets secondaires potentiels des traitements disponibles, il est essentiel qu'un diagnostic précis soit posé avant que quelque traitement soit envisagé pour le patient. Il est impératif, d'un point de vue médical, d'avoir un portrait clinique assez juste afin d'orienter le patient vers le traitement qui lui convient le mieux.

A la lecture de cet article, tout dentiste prudent se rend bien compte que le diagnostic de cette condition sort de son champ de compétence. L'apnée du sommeil et le ronflement sont des conditions médicales. Toutefois, certains cas peuvent être traités par des dentistes, sous ordonnance. Il a été démontré que les appareils

dentaires réduisent les épisodes d'apnée efficacement sur une période prolongée et ont un excellent taux d'utilisation.<sup>9</sup>

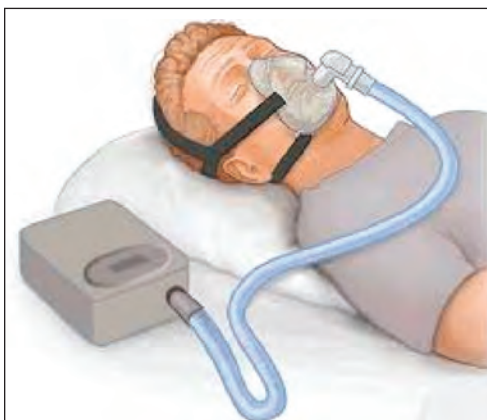### Les appareils de traitements

Le traitement le plus populaire pour l'apnée du sommeil est l'APPC ou Appareil à Pression Positive Continue. (CPAP en anglais). Cet appareil, constitué d'une composante de ventilation et d'un masque facial, fonctionne en soufflant de l'air sous pression dans les voies respiratoires, les dégageant et permettant au patient de respirer. L'APPC est un traitement très efficace, mais son principal inconvénient est le taux d'adhérence au traitement, qui est relativement bas.<sup>11</sup> Selon les recommandations de la Canadian Sleep Society, l'APPC est particulièrement indiqué dans les cas d'apnée sévère, modérée ou accompagnés de forte symptomatologie, en première ligne.

Lorsqu'acheté d'une compagnie respiratoire, le coût d'un APPC peut varier, impliquant plusieurs milliers de dollars, tout dépendant du type de machine sélectionné et des accessoires inclus. Au Québec, le régime de la RAMQ ne couvre pas l'achat de ces appareils, qui sont par ailleurs généralement bien couverts par les régimes d'assurance privée.

Les appareils dentaires, quant à eux, utilisent surtout le principe de l'avancement mandibulaire. D'autres appareils retenant la langue en position antérieure sont aussi disponibles, mais leur usage est plutôt marginal. En stabilisant la mandibule dans une position avancée, on se trouve à reconfigurer les voies respiratoires supérieures, facilitant le passage de l'air et éliminant les épisodes d'obstruction respiratoire. Les appareils dentaires sont particulièrement indiqués dans les cas de ronflement seulement, dans les cas d'apnée légère ou modérée, sans trop de symptômes. On peut aussi les utiliser dans les cas d'apnée sévère, en cas d'échec du APPC.

Fig 4: Illustration de l'Appareil à pression positive continue (APPC)<sup>10</sup>





Il n'existe pas d'échelle fixe de prix pour le traitement et le suivi de ces appareils, mais en discutant avec différents praticiens, la valeur de ces services implique des déboursés de plusieurs milliers de dollars. Le remboursement auprès des assureurs peut être problématique et fonctionne souvent au cas par cas.

Une étude récente comparant l'APPC aux appareils dentaires dans un groupe de cas sévères, conclut que les 2 alternatives de traitement ont une efficacité globale comparable: bien que l'APPC est plus efficace qu'un appareil dentaire, le fait que le patient utilise l'appareil dentaire pour un nombre d'heures plus élevé que l'APPC fait que l'efficacité globale de ces 2 options de traitement est comparable.<sup>12</sup>

Qu'en est-il des appareils dentaires disponibles en vente libre? Leur existence remonte à près d'une vingtaine d'années. Leur utilisation est limitée puisque leur efficacité et la possibilité de s'acclimater à leur utilisation est restreinte par le fait qu'ils ne sont pas faits sur mesure, ce qui diminue grandement le confort du patient. L'effet pervers de ces appareils est que souvent, ils découragent des patients qui seraient d'excellents candidats pour des appareils dentaires faits sur mesure, car leurs appareils génériques sont trop inconfortables ou inefficaces. La littérature scientifique rapporte une efficacité et une compliance inférieure de 50% par rapport à un appareil fait sur mesure.<sup>13</sup>

Alors que les professionnels de la santé sont soumis à des standards de pratique rigoureux, visant à optimiser les taux de succès, les appareils dentaires en vente libre ne sont soumis à aucun contrôle. Ils donnent l'illusion aux patients qu'ils peuvent se diagnostiquer, sélectionner le traitement qui leur convient le mieux et gérer eux-mêmes les effets secondaires qui pourraient survenir. Le public n'est pas protégé par cette approche, qui comporte son lot de danger. Le cas clinique qui suit illustrera ce point.

### Cas Clinique

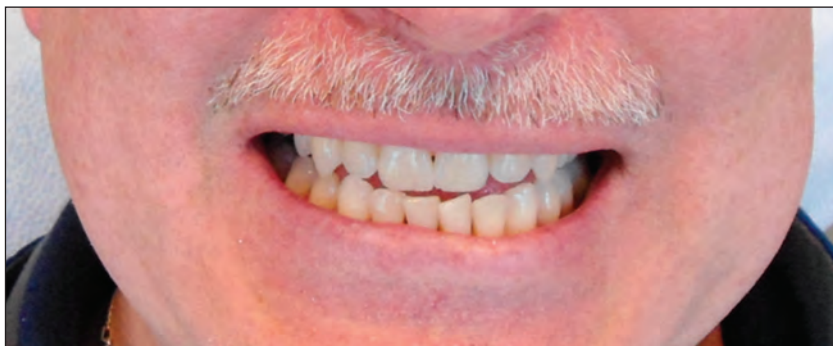Homme de 49 ans se plaignant de troubles de ronflement. Il ressent beaucoup de fatigue et peine à rester concentré durant la journée.

Sa condition dentaire est stable depuis plusieurs années et il démontre une occlusion de classe 1. Son médecin de famille ne l'avait jamais référé pour une étude du sommeil. En faisant des recherches en ligne, il trouve plusieurs sites où, à peu de frais, il peut se procurer un appareil dentaire pour traiter les troubles de ronflement.

Initialement, le traitement semble efficace, mais le ronflement et la fatigue refont leur apparition après un mois ou deux. Par la suite, le patient éprouve de la douleur à l'articulation temporo-mandibulaire et aux dents, et éprouve de la misère à bien mastiquer ses aliments. Lors de sa visite d'examen préventif, le dentiste omnipraticien qui l'examine régulièrement constate que le patient est en occlusion ouverte et que seuls des contacts entre les dents 27 et 37 sont présents. Une analyse sommaire montre que le patient est rendu avec une occlusion de classe 3 squelettique. Si on tente d'articuler les modèles ensemble, l'emboîtement est bon. Malgré des traitements conservateurs impliquant l'intervention d'un physiothérapeute et l'utilisation de plaque occlusale, il n'est pas possible de retrouver une occlusion satisfaisante.

Le patient est référé en orthodontie, où l'on considère une approche ortho-chirurgicale pour rétablir une occlusion satisfaisante et éliminer les troubles d'apnée du sommeil, tel que décrits dans la littérature.<sup>14</sup> En parallèle avec les traitements que nous avons effectués au niveau de l'occlusion, le patient est aussi référé pour évaluer l'étendue réelle de ses troubles de ronflement. Le diagnostic d'apnée du sommeil modéré avec symptômes est confirmé. Le médecin spécialiste prescrit un APPC, lequel est bien toléré par le patient.

En résumé, ce qui semblait être au départ un cas de ronflement s'est révélé être un cas d'apnée du sommeil, avec les conséquences possibles sur la santé du patient. L'absence de diagnostic (on ne savait pas ce qu'on traitait réellement), l'utilisation d'un appareil inapproprié pour la situation ainsi que le manque de suivi ont fait que ce patient s'est retrouvé avec des complications beaucoup plus coûteuses, financièrement et biologiquement, que si la séquence normale de traitement avait été suivie. De plus, compte tenu des complications subies, il est



**Fig. 5: Fermeture acquise démontrant l'avancement de la mandibule en Classe 3 suite au port d'un appareil dentaire en vente libre**

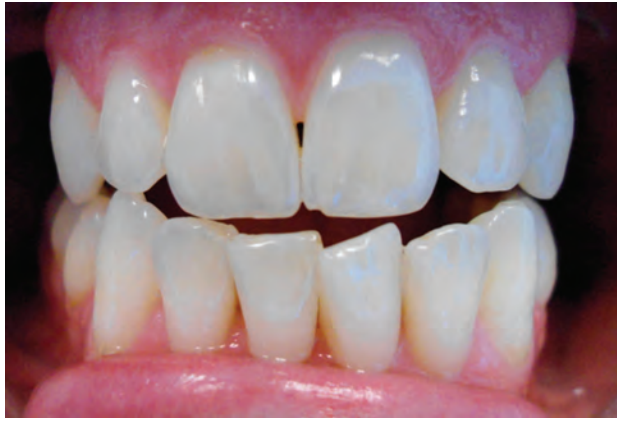

Fig. 6 a) absence de contacts antérieurs;

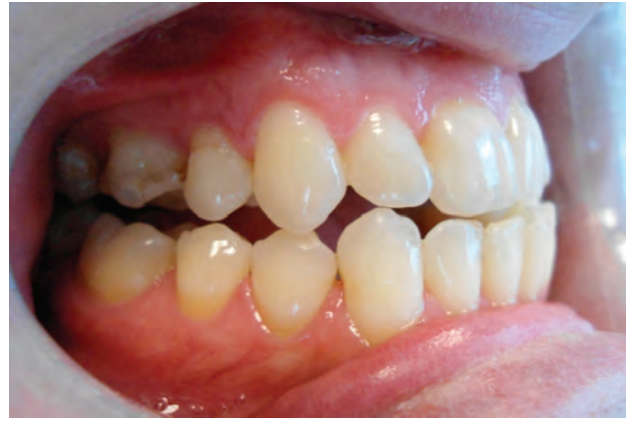

Fig. 6 b) absence de contacts postérieurs

évident que le patient n'est pas intéressé à utiliser un appareil dentaire pour traiter ses troubles d'apnée du sommeil dans le futur. Je suis convaincu que si initialement un appareil dentaire adéquat avait été sélectionné et que le suivi avait été bien fait, aucune de ces complications ne seraient survenues. En tentant de sauver quelques milliers de dollars, le patient s'est infligé des dommages qui lui coûteront cinq fois plus que ce qu'il pensait sauver.

Dans notre deuxième article sur le traitement des troubles d'apnée du sommeil et de ronflement, nous verrons plus en détails les différents types d'appareils dentaires disponibles et utilisés par les dentistes, leurs effets secondaires et les principes guidant la prise en charge des complications possibles.

### À propos de l'auteur

Dr David Côté a obtenu son doctorat en Médecine Dentaire de l'Université de Montréal en 1996. Il est établi en pratique privée à Gatineau depuis 1998. Dès sa graduation, Dr Côté s'est intéressé au traitement du ronflement et de l'apnée du sommeil à l'aide d'appareils dentaires. Dr Côté est membre de l'American Academy of Dental Sleep Medicine, il est Diplômé de l'American Board of Dental Sleep Medicine et membre fondateur de la section Dentaire de la Canadian Sleep Society. Il travaille notamment en collaboration avec la clinique Neuro Outaouais et avec l'hôpital d'Ottawa dans le traitement de l'apnée du sommeil.

### Bibliographie

- 1) Fleetham J., Ayas N., Bradley d., Ferguson K., Fitzpatrick M., George C., Hanley P., Hill F., Kimoff J., Kryger M., Morrison D., Series F., Tsai W., Directives de la Société Canadienne de Thracologie: Diagnostic et traitement des troubles respiratoires du sommeil de l'adulte. *Can Resp J* 2006; 13(7) :387-392
- 2) [www.orthoapnea.com](http://www.orthoapnea.com)
- 3) [www.sommeil-mg.net](http://www.sommeil-mg.net)
- 4) Gauthier L., Almeida F., Arcache JP, Ashton McGregor C., Côté D., Driver HS., Ferguson KA., Lavigne GJ., Martin P, Masse JF, Morisson F., Pancer J., Samuels CH., Schachter M., Series F., Sullivan GE., Position paper by Canadian Sleep medicine professionals on the role of different health care professionals in managing obstructive sleep apnea with oral appliances. *Can Respir J* 2012 Sept-Oct; 19(5):307-9
- 5) Points saillants de l'Enquête sur la santé dans les collectivités canadiennes de 2009-Réponses rapides sur l'apnée du sommeil, Publication de l'Agence de la santé publique du Canada, 2009

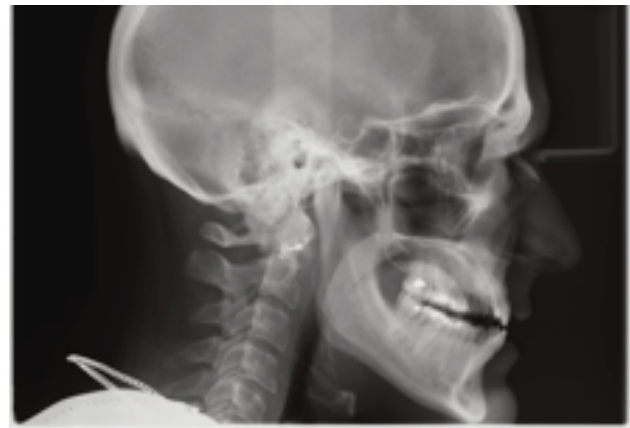

Fig.7: Céphalogramme démontrant le déplacement antérieur du condyle et les béances occlusales généralisées

- 6) Marshall NS., Wong KK., Liu PY., Cullen SR., Knuiman MW., Grunstein RR, Sleep apnea as an independent risk factor for all-cause mortality: the Brusselton Health study, *Sleep* 2008 Aug; 31 (8) 1079-85
- 7) Sjostrom C., Lindberg E., Elmasry A., Hagg A., Svardsudd A., Janson C., Prevalence of sleep apnea and snoring in hypertensive men: a population based study, *Thorax* 2002 Jul; 57(7):602-7
- 8) Buratti L., Vittichi G., Falsetti L., Cagnetti C., Luzzi S., Bartolini M., Provinciali L., Silvestrini M., Vascular impairment in Alzheimer's disease: the role of obstructive sleep apnea. *J. Alzheimers dis.* 2014 Jan 1; 38(2) 445-53
- 9) Horstmann S., Hess CW., Bassetti C., Gugger M., Mathis J., Sleepiness-related accidents in sleep apnea patients, *Sleep* 2000 May 1;23(3):383-9
- 10) [http://en.wikipedia.org/wiki/Positive\\_airway\\_pressure](http://en.wikipedia.org/wiki/Positive_airway_pressure)
- 11) Gauthier L., Laberge M., Beaudry M., Laforte M., Rompré PH., Lavigne GJ., Mandibular advancement appliance remain effective in lowering respiratory disturbance index for 2.5-4.5 years., *Sleep med.* 2011 Oct; 12(9):844-9
- 12) Boyaci H., Gakar K., Bans SA., Basyiqit I., Yildiz F., Positive airway pressure device compliance of the patients with obstructive sleep apnea syndrome., *Adv Clin Exp Med.* 2013 Sept-Oct;22(6):809-15
- 13) Sutherland K., Vanderveken OM., Tsuda H., Marklund M., Gagnadoux F., Kushida CA., Cistulli PA. Oral appliance treatment for obstructive sleep apnea: an update. *J Clin Sleep Med* 2014 Feb 15; 10(2): 215-227
- 14) Vanderveken OM., Devolder A., Marklund M., Boudewyns AN., Braem MJ., Okkerse W., Verbraeken JA., Franklin KA., De Backer WA., Van de Heyning PH., Comparison of a custom made and a thermoplastic oral appliance for the treatment of mild sleep apnea. *Am J Crit Care Med* 2008 Jul 15;178(2): 197-202
- 15) Li KK., Maxillomandibular advancement for obstructive sleep apnea. *J Oral Maxillofac surg* 2011 Mar; 69(3):687-94.

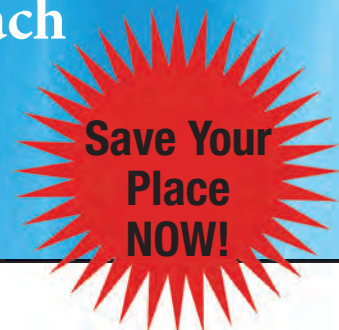Oral Surgery Academy for General Dentists presents:  
The most successful course on...

# Oral Surgery for the GP: A Practical Approach

Dr. Lawrence I. Gaum DDS, FADSA, FICD, FADI, Cert. Anaesthesia

A 3-Day Hands-On Seminar

with a NEW component on diminished (atraumatic) extractions!



New 2014 Dates		Few Spots Left	
Fort Lauderdale	Toronto	Toronto	Denver Colorado
<del>March 14-16, 2014</del> <b>SOLD OUT!</b> 1700 Crum Creek Rd, Dania Beach, FL	<del>April 25-27, 2014</del> <b>SOLD OUT!</b> 672 Applewood Cres, Vaughan, ON	October 24-26, 2014 Hilton Toronto/Markham Suites 8500 Warden Ave, Markham, ON	November 14-16, 2014
<b>\$2395 + HST</b> ■ Includes a \$499 Lab Fee			



To register contact:

Palmeri Media Group at 905.489.1970 ext 206 / 207 or

Email: [events@palmeripublishing.com](mailto:events@palmeripublishing.com) / [seminars@palmeripublishing.com](mailto:seminars@palmeripublishing.com)

21 credits for seminar attendance

**The Most Sold Out Oral Surgery Course in North America!**  
**You Won't be Disappointed!**



Course price includes  
Oral Surgery book and DVD

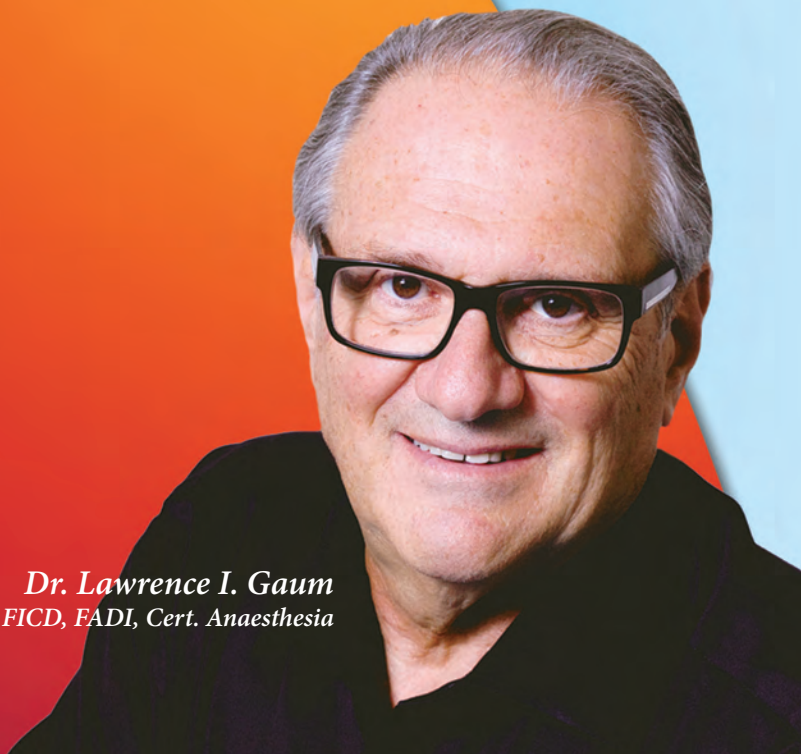

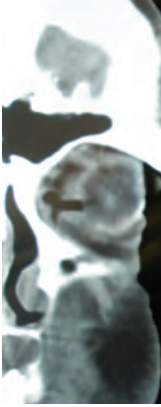
Palmeri Media Group  
Phone: 905.489.1970  
Fax Orders: 905.489.1971



Approved PACE Program Provider FAGD/MAGD Credit  
Approval does not imply acceptance by a state  
or provincial board of dentistry or  
AGD endorsement 9/1/2013 to 8/31/2015  
Provider ID# 355116

**Dr. Lawrence I. Gaum**  
DDS, FADSA, FICD, FADI, Cert. Anaesthesia





Dr. Engin Aras<sup>1</sup>,  
Cukurova I.<sup>2</sup>,  
Sonmez M.<sup>3</sup>,  
Aladağ A.<sup>4</sup>,  
Saygi T.<sup>5</sup>,  
Sahan H.T.<sup>5</sup>

## Minimal Invasive Augmentation with Delayed Tunnel Technique and Rehabilitation of Cyst Patients with Implant Supported Dentures

A CLINICAL STUDY

## Augmentation minimale peu invasive avec une technique de tube secondaire et réhabilitation de kystes pour les patients ayant des prothèses implanto-portées

Étude clinique

### Abstract

**Objectives** - The purpose of this study was to shorten the postsurgical recovery period, to create favorable preprosthetic conditions, and open access to advanced prosthetic treatment modalities for cystectomy patients with postsurgical defects and advanced bone loss.

**Materials and methods** - Techniques for the treatment of upper and lower jaw cysts involve marsupialisation or enucleation. In large lesions both of these procedures leave extensive defects after surgery with long recovery periods. This article describes an alternative three stage approach to developing a favorable site by using the delayed tunnel technique, augmentation with an an allograft material and restoration with an implant supported denture.

**Results** - In this retrospective study, the procedures and results of thirty-four cyst cases were evaluated. Eleven of these cases were rehabilitated with the delayed tunnel technique, subperiosteal grafting and implant supported dentures. The remaining twenty-three cases were treated only with marsupialisation and decompression due to anatomic location and unsuitability for the tunnel technic. The described three stage approach provided favorable dimensions and a stronger base for the implant supported restorations in a shorter period of time.

**Discussion and conclusions** - Slow osteoblastic repair of postsurgical cyst defects, especially in the senior edentulous patients, prolongs the preprosthetic recovery period, delays the prosthetic treatment and creates esthetic, functional and psychological problems. In addition, knife edge ridges and undercuts at the cyst defect walls may also complicate the prosthetic treatment. The modified approach was applied in three stages: 1.marsupialisation, 2.delayed tunnel operation, augmentation and implant placement 3.Implant supported prosthetic restoration. The "Tunnel Technique", an often used procedure in oral implantology and periodontology is here applied for the first time in the treatment of cyst defects. This three stage modified approach, minimized the preprosthetic recovery period after tunnel technique and augmentation, increased the quality of prosthetic rehabilitation and improved the patients' quality of life.

**Key words:** cysts, marsupialization, decompression stents, tunnel technique, allografts, implants



**Objectifs** - Le but de cette étude était de réduire le temps de rétablissement post-opératoire, de créer des conditions favorables pré-prothétiques, et d'ouvrir l'accès à des modalités de traitements prothétiques avancés dans des kystectomies pour les patients avec des défauts post-chirurgicaux et une perte osseuse avancée.

**Matériaux et méthodes** - Les techniques de traitement de kystes des mâchoires, comprennent la réduction ou l'ablation. Dans le cas des grandes lésions, ces deux procédures entraînent de grandes imperfections après la chirurgie, accompagnées de longues périodes de récupération. Cet article décrit une approche alternative, en trois étapes, pour développer un siège favorable, en utilisant la technique de tube secondaire, le rajout d'un matériau d'allogreffe et une restauration au moyen d'une prothèse implanto-portée.

**Résultats** - Dans cette étude rétrospective, les procédures et résultats de 34 cas de kystes furent évalués. Onze de ces cas ont subi une réhabilitation avec la technique des tubes secondaires, greffe sous-périostée et des prothèses implanto-portées. Les autres 23 cas furent traités uniquement avec réduction et décompression, du à leur emplacement anatomique et à une contre-indication de la technique des tubes secondaires. L'approche décrite des trois étapes donne des dimensions favorables et une base plus solide pour les restaurations implanto-portées, et ceci, dans un temps plus court.

**Discussion et conclusions** - Une lente réparation ostéoblastique post-chirurgicale des imperfections kystiques, surtout chez les patients âgés édentés, prolonge la période de récupération pré-prothétique, retarde le traitement prothétique, et crée des problèmes esthétiques, fonctionnels et psychologiques. De plus, des crêtes en lames de couteau et en contre-dépouilles au niveau des parois défectueuses des kystes, peuvent également compliquer le traitement prothétique. L'approche modifiée fut réalisée en 3 étapes : 1. réduction 2. application retardée des tubes secondaires, augmentation et placement d'implant 3. restauration implanto-portée. La « Technique des tubes », souvent utilisée en implantologie orale et en parodontie, est ici mise à contribution pour la première fois pour le traitement des imperfections kystiques. Cette approche en trois étapes modifiée, réduit la période de guérison pré-prothétique après la technique des tubes et l'augmentation, accroît la qualité de la réhabilitation prothétique et améliore la qualité de vie des patients.

**Mots clé** - kyste, réduction, gouttière de décompression, technique des tubes, allogreffe, implant

**T**ill recently, techniques for the treatment of upper and lower jaw cyst involved marsupialisation or enucleation. In large lesions both of these procedures leave extensive defects after surgery with long recovery periods. This article, a retrospective study, describes an alternative three stage approach to developing a favorable site by using the delayed tunnel technique, augmentation and restoration with an implant supported denture. Slow osteoblastic repair of postsurgical cyst defects especially in the senior edentulous patients, prolongs the preprosthetic recovery period, delays the prosthetic treatment and create esthetic, functional and psychologic problems. In addition, knife edge ridges and undercuts at the cyst defect walls may also complicate the prosthetic treatment. In this study, the modified approach was applied in three stages:

1. marsupialisation,
2. delayed tunnel operation, augmentation and implant placement

3. Implant supported prosthetic restoration. This modified approach minimized the preprosthetic recovery period after the tunnel technique and augmentation, increased the quality of the prosthetic rehabilitation and improved the patients' quality of life.

#### What is new ?

- Subperiosteal grafting with “delayed tunnel technique” and implant insertion soon after marsupialisation.

#### What is the benefit?

- Faster recovery. Decreases the recovery period after augmentation from years to a few weeks
- Provides more favorable dimensions, and a stronger base for implant supported prosthetic reconstructions

## How?

- Due to decompression, the cyst lining on the base and lateral walls of the cystic cavity thickens in 4-8 weeks after marsupialisation and this tissue optimization allows for the tunnel technique and augmentation with allograft material
- Sharing of functional loads by the implants and the denture can minimize the stresses on the graft site, thus promoting osteoblastic activity, protecting the site and morphology

## Introduction

Cysts in the mouth are pathologic cavities lined by epithelium, filled with serosanguinous fluid and some cholesterol crystals. Odontogenic and non-odontogenic cystic lesions in the maxilla (Fig.1a) or in the mandible (Fig. 2a) often result in considerable destruction of these bones<sup>1,2,3,4,5,13,21</sup>. Defects created by surgery of large cysts, have delayed recovery periods<sup>12,14,18</sup> which in turn prolong the prosthetic rehabilitation of these patients. Enucleation with primary closure, marsupialization (Fig. 1b) or the Partsch operation, decompression and reconstruction were the main treatments of choice. But it has also been reported that enucleation and immediate reconstruction may present complications,<sup>7,8,9,11</sup> especially in cases of infected cystic lesions. When the surgical removal of a large maxillary or mandibular cyst results in a large osseous defects, long periods of time are required for bone regeneration to repair the defect.<sup>6,10,11</sup> Prostheses used during the treatment of these lesions are called “decompression stents”. Following surgery, decompression stents relieve the cystic pressure, allow the cyst lining on the base and lateral walls of the cystic cavity to thicken in 4-8 weeks, allow some bone regeneration on the base and the lateral walls of the defect and permit the cystic cavity to become smaller. But it may take years for the large cysts to recover. The recovery is faster in young patients with cysts. Decompression stents keep the drainage canal open by preventing the closure of the drainage canal with osteoblastic activity, and also keep the defect cavity cleaner by preventing food accumulation<sup>11,12,13</sup>. The orifice of the cyst has to be kept open by decompression stents, till complete obliteration of the cavity.<sup>14</sup> In relation to the time of surgery and the technique used, decompression stents are

defined as surgical decompression stents (Fig. 1c, 1d) or postsurgical decompression stents, the immediate removable partial denture stents,<sup>2</sup> the complete denture stents,<sup>3</sup> the temporary drainage stents<sup>4</sup> and the custom-made perforated decompression stents.<sup>15,16,17,18</sup>

When the path of insertion of the decompression stent into the cystic cavity is parallel to the path of insertion of the removable dentures, decompression stents may be attached to the removable dentures<sup>11,12,15,16,17,18</sup>. This was a common practice in days when the teeth in the cystic area were thought to be unsalvageable by endodontic treatment and apicoectomy. Nonvital teeth were extracted during initial surgery and a vertical access was created to the cystic cavity. An acrylic resin or a plexiglass tube was attached to the removable denture to decompress the cystic content.<sup>12,15,16,17,18</sup> For almost more than two decades, two considerations have gained more acceptance in the treatment of cystic lesions. The first consideration is to save teeth, where possible, with endodontic therapy and apicoectomy. The second modification is the lateral surgical approach through the wall of the cyst cavity and the regression of the cystic cavity with the use of decompression stents. This helps to minimize the bone loss and protects the vertical dimensions of the alveolar crest.<sup>6,8,14,18</sup> Since enucleation and immediate reconstruction presented complications especially in infected cases, marsupialisation and spontaneous recovery of the exposed cyst defect remained the only solution for a longtime.<sup>7,12,13,14</sup>

The tunnel technique and the allograft augmentation materials, as applied in noninfected fields in periodontology and in oral implantology<sup>4,19,20,22</sup> opened a new avenues for the reconstructions of our cyst defect cases.

## Materials and methods

In this retrospective study, the procedure and the results of thirtyfour cases (Tables. 1 and 2) were evaluated. Eleven of these cases were rehabilitated (Table 3) with the delayed tunnel technique, subperiosteal grafting and implant supported dentures. The remaining twentythree cases were treated only with marsupialisation and decompression due to anatomic location and the unsuitability for the tunnel technique. Informed consents

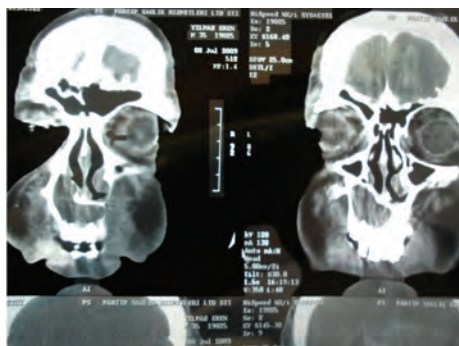


Fig. 1a. Odontogenic cyst in the upper jaw- Level teeth #1-9

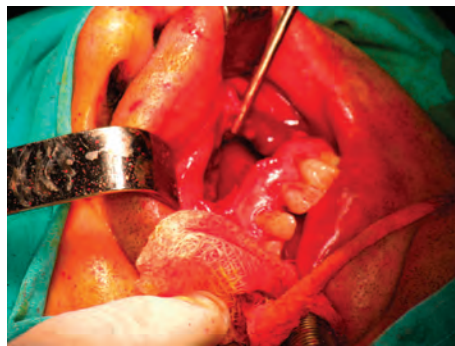

Fig.1b. Marsupialization for an anterior maxillary odontogenic cyst

TYPE OF LESION	NUMBER OF CASES
Dentigerous cyst	7
Odontogen keratocyst	6
Radicular cyst	9
Keratocyst	10
Giantcell granuloma	2
Age range	10 - 64
Age average	39
Total number of cases	34

Table 1. Types of the cystic lesions studied, age range, age average and number of cases

TYPE OF LESION	NUMBER OF CASES
Treatment procedure	7
Marsupialization and decompression	6
Marsupialization, decompression, tunnel operation with allograft	9
Endodontic treatment in conjunction	10

Table 2. Treatments procedures

PREPROSTHETIC TIMING				
STAGE	PHASE	PURPOSE	TIMING	PROSTHESIS
I	POST MARSUPIALISATION	MUCOPERIOSTEAL FORMATION ON CYST BASE/WALLS	4-8 WEEKS	SURGICAL DECOMPRESSION STENT
II	1.TUNNEL TECHNIC 2.AUGMENTATION 3.ENDOSSEOUS IMP.	OSSEO - INTEGRATION	3 MONTHS BETWEEN 4.WEEK-16.WEEK	TEMPORARY CD/RPD/FPD
III	FINAL PROSTHESIS	FUNCTION & AESTHETIC	AFTER 4TH MONTHS	EOI SUPPORTED CD/RPD OR FPD

Table 3. Procedure, purpose, timing and type of the appliance used.

were taken preoperatively from every patient before the procedure. The patients were fully informed about the treatment procedures.<sup>4,19,20,22</sup> Where possible the teeth were preserved. Following marsupialization (Fig. 1b), the defect cavity was allowed to reduce in size by continuous decompression with stents in every case. Surgical decompression stents were prepared with silicone putty (Fig. 1c, 1d) and postsurgical decompression stents were prepared with heat cure acrylic resin. After an average decompression period of four to eight weeks, eleven of our the thirtyfour cyst cases had an augmentation procedure using the subperiosteal tunnel technique using an allograft material\*.

In large defects, 4-8 weeks following marsupialisation, the soft

tissue lining at the base of the cystic cavity thickens and gets a more resistant tissue appearance, strong enough for tunnelling and the subperiosteal grafting (Fig. 2b). At this stage the tunnel technique and the superosteal grafting with an allograft\* were applied if the cyst cavity had no connection with the nasal fossae nor with the sinuses. The concave shape of the defect base, provided an abundant amount of soft tissue cover when mobilised from the base of the cavity, to form a tension free surface on the roof of the cavity. An unilateral vertical incision similar to the augmentation procedures in knife edge ridge cases, but longer was made (Fig. 2c, 2d). The periosteum covering the base and lateral walls of the cyst cavity was undermined and, the space thus created between the bone and the

\* Miner Oss., 2300 Riverchase Center, Birmingham, AL 35244, USA

\*\* Bicon Implants, 501 Arborway, Boston, MA 02130, USA

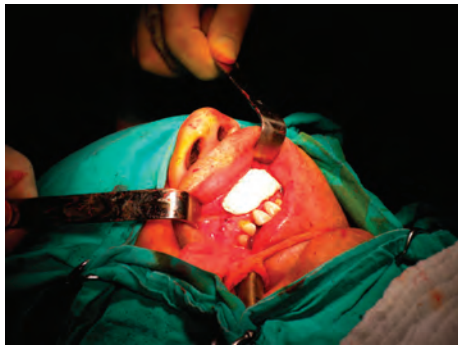

Fig. 1c. Surgical decompression stent in cyst cavity

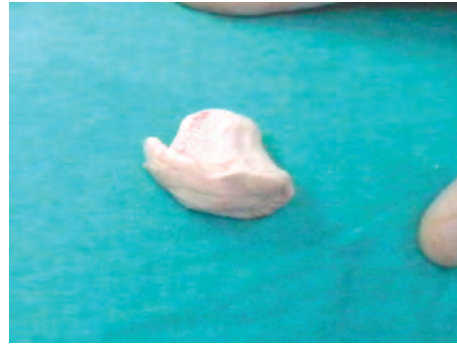

Fig. 1d. Anterior and posterior sections of the surgical decompression stent

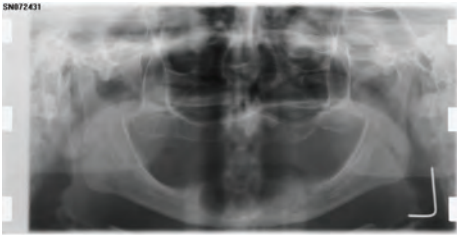


Fig. 2a. A preoperative OPG of the lower cyst

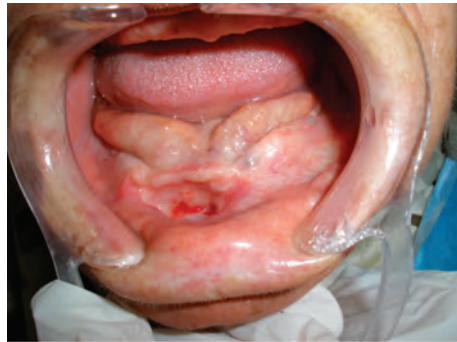

Fig. 2b. Post-surgical cyst defect in anterior mandible

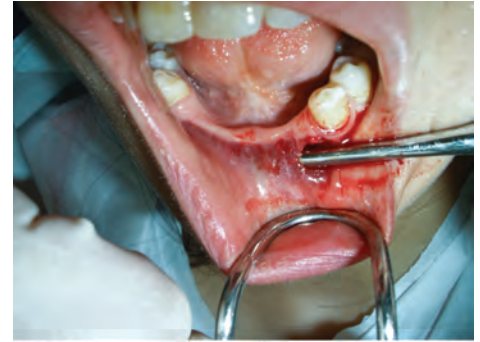

Fig. 2c. Shorter incision for a tunnel approach in a knife edge ridge case

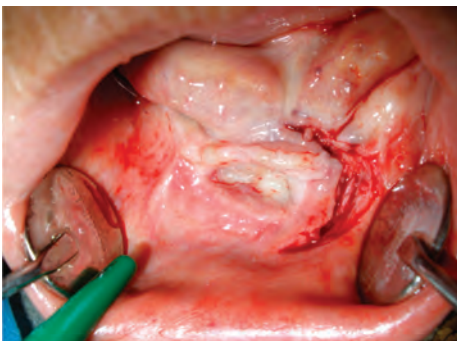

Fig. 2d. Longer incision for a tunnel approach on an anterior mandibular cyst defect to better mobilize the basal lining of the defect area. Incision was made about two centimeters distal to the cyst defect

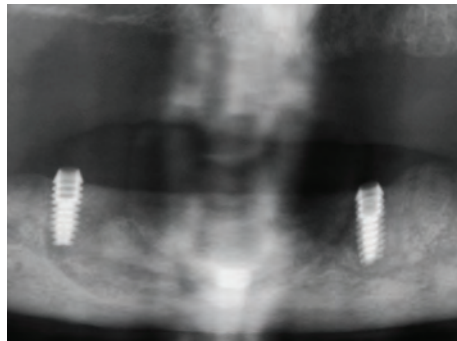


Fig. 2e. Three months after bone grafting\* and Bicon endosseous implants\*\*

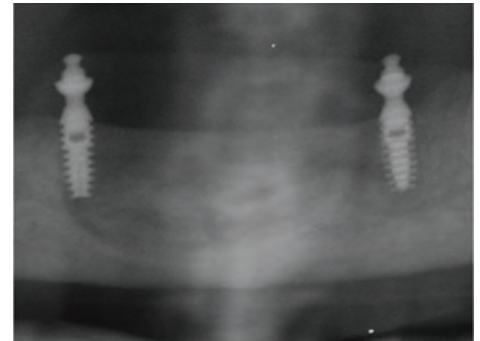


Fig. 2f. Six months after implant surgery. Brevis Abutments\*\* for a mandibular implant retained overdenture.

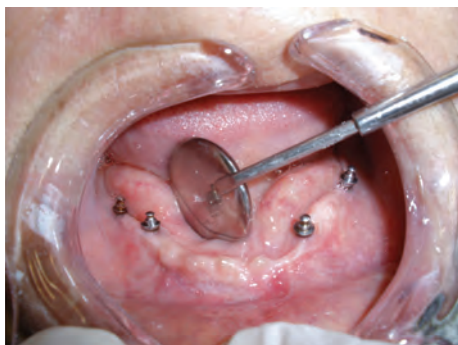

Fig. 2g. Quadrilaterally positioned Bicon implants and Brevis abutments to support a mandibular complete denture.

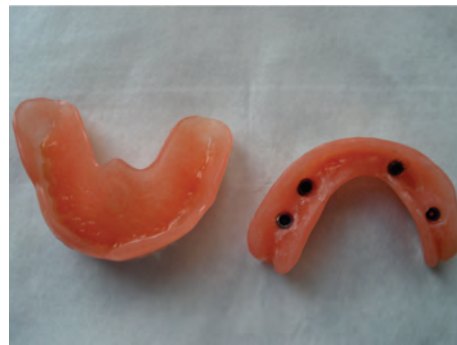

Fig. 2h. Lower complete denture with rubber/retention O rings



periosteum was filled with the allograft material\*. This restored the defect previously created by the cyst. The tunnel technique incision we used in cyst defect reconstructions (Fig. 2d) were longer than the regular tunnel technique incision in knife edge ridge augmentation cases (Fig. 2c). This provided more elasticity for the cover tissue and prevented any tear of the periosteum. The prosthetic treatment of edentulous patients; with tunnel operation and augmentation but without endosseous implants were initiated one month after the augmentation when the hematoma in the operation area subsided and soft tissues healed totally. When implants\*\* were placed in non-augmentation zones, regular osseointegration periods were observed. The prosthetic treatment of patients with tunnel operation/augmentation and with endosseous implants\*\* in the augmentation zone, were initiated after their radiologic control (Fig 2e, 2f) and verification of implant osseointegration. In this study, prosthetic loading in grafted zones was delayed by twice as much time when compared with regular zones for better osseointegration purposes.

### Daily care

The patients were instructed about oral hygiene, the care of the operation site and the prosthesis. During the decompression period, the stents were removed, the teeth and the stent brushed and the cavity cleansed using a sodium chloride/bethadine solution after every meal. The patients were recalled monthly for the follow up and vertical reduction of the decompression stents. After every adjustment, the decompression stents were repolished to prevent any trauma. After the delivery of the implant supported definitive prosthesis, the patients were instructed about the care of their oral hygiene and dentures once more.

### Discussion

Since 1960s two options existed for the treatment of maxillary and mandibular cysts: marsupialisation (Partsch I) or enucleation.<sup>1,2,11,12,13,14</sup> Some researchers have noted that enucleation with primary closure (Partsch II) or enucleation with primary closure and bone grafting are rarely successful especially in infected cases.<sup>2,9,10,11,13</sup> The third option, which was the subject of our study, is a combined procedure. It includes marsupialisation, decompression with stents, reconstruction with the delayed tunnel technique and augmentation with an allograft and implant supported dentures. This proved to be a safe and successful procedure. Marsupialisation and decompression techniques permit observation for any malignant transformation in the operation site and also allow regression of the cystic cavity. Delayed tunnelling and augmentation techniques, as applied here for the first time in the reconstruction of cyst defects, provide safer and faster conditions for the reconstruction of the postoperative cystic defects. The lateral approach to the cystic cavity rather than a vertical approach minimizes the loss of vertical alveolar bone support and preserves more bone for the post surgical prosthetic rehabilitation. Contemporary

graft materials and the delayed tunnel surgery technique shortened considerably the preprosthetic recovery period of these patients, when the cyst cavity is not in connection with the sinuses and the nasal fossae. Surgical procedures permitting observable recovery techniques such as the Partsch technique and the decompression stents, seem to be safer for the patients<sup>6,9,13,16,17,18</sup> when recurrence of the lesion is within the probabilities. The delayed tunnel technique with augmentation and prosthetic restoration with implant supported dentures as applied in this study, helped our patients to regain their esthetic and function in shorter periods of time when compared to the decompression technique alone, and proved to be more successful and safer than enucleation, primary closure and grafting.

### Summary

This retrospective clinical study describes a three stage approach in the treatment of the upper and lower jaw cysts. The "Tunnel Technique", an often used procedure in oral implantology and periodontology is here applied for the first time in the treatment of cyst defects. The advantages of this approach is that it restored the defect site safely in a shorter period of time, it provided favorable dimensions and a stronger base for the implant supported restorations.

### Conclusion

It is observed in this study that the use of delayed tunnel technique and augmentation with an allograft after marsupialisation of the maxillary and mandibular cysts provided an earlier recovery, more favorable dimensions and a solid base for the implant supported restorations.

### About the authors

- <sup>1</sup>DDS, DDS, CES, Ph.D. Professor and Former Head, Department of Prosthodontics, Ege University, Faculty of Dentistry, Izmir, Turkey and Grenfell Regional Health Service, SBIHC Dental Department, Flower's Cove, NL AOK 2N0, Canada, arasmeister@gmail.com
- <sup>2</sup>Head, ORL and Head and Neck Surgery Dept., R&Post Graduate Training Hospital, Tepecik, Izmir, Turkey.
- <sup>3</sup>Head, Department of Prosthodontics and Oral Implantology, CTG Dental Hospital, Izmir, Turkey
- <sup>4</sup>DDS, Ph.D., Associate Professor, Department of Prosthodontics, Ege University, Faculty of Dentistry, Izmir, Turkey
- <sup>5</sup>DDS, Ph.D, Research Associate, Ege University, Faculty of Dental Medicine, Izmir, Turkey

*Financial Interests: The authors have no financial interest with the products mentioned in the article.*

# Academy News/ Nouvelles de l'académie

CARDP Fellow member, Dr. Allan Coopersmith, becomes Fellow of the American College of Dentists at its recent Annual Meeting in New-Orleans.



"The American College of Dentists (ACD) is the oldest major honorary organization for dentists. Its members have exemplified excellence through outstanding leadership and exceptional contributions to dentistry and society.

In response to serious problems facing the profession, the American College of Dentists was founded August 20, 1920, by the then leaders of dentistry to elevate the standards of dentistry, to encourage graduate study, and to grant Fellowship to those who have done meritorious work. The American College of Dentists is nonprofit and apolitical, and has long been regarded as the "conscience of dentistry." <https://www.acd.org>

## Featuring a Life Member from Manitoba

Last September's CARDP Meeting in Vancouver gave me a wonderful opportunity to rekindle my longtime bond with Allan Osborn and his wife Hazel while visiting Victoria. Going over the highlights of Allan's professional career and contributions to the dental field, allowed me to appreciate yet again the quality and high standards that CARDP's membership embodies.



Dr. Allan Osborn and his wife Hazel, enjoying retirement in Victoria, BC.

I had the pleasure to work closely with Allan and his collaborators for the 2005 Annual Meeting in Québec City. He had been a frequent scientific contributor

to many CARDP meetings and also served as its President. Through my various contacts with Allan, I also discovered another of his talents, as a linguist, conversant in German, Japanese and French.

After bidding farewell to the Osborns on peaceful Vancouver Island, I understood why I had sought him out after so many years. His unwavering passion for Dentistry and his kind, generous personality are at the core of what our membership stands for.

I wish you, Allan and Hazel, a continued happy retirement and thank you most sincerely for your gracious fellowship in the advancement of CARDP. All the best to both of you my friends. Here is Allan's condensed CV.

Dr. Hubert Gaucher - Editor-in-Chief

**BALUKE**  
DENTAL STUDIOS  
Dedication, Precision, Reliability.™

Full Service

**Digital Dental Lab**

Providing dentistry since 1947.

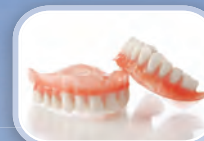

[www.baluke.com](http://www.baluke.com)

1.800.263.3099



**COSMETICS**



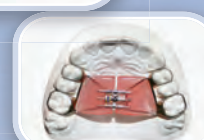**DENTURES & PARTIALS**

**CROWN & BRIDGE**  
Screw Retained Crowns & Implant Abutments



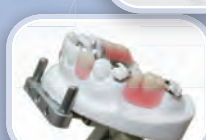**ALL REMOVABLE PROSTHODONTICS**

**CAD/CAM PRECISION**  
Treatment Planning / Guided Surgery



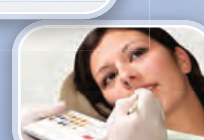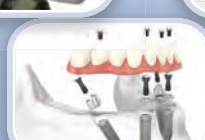
**ORTHODONTICS**

**CAD/CAM PARTIAL DESIGNS**



**DIGITAL IMPRESSION SCAN PARTNERS**

**IMPLANT OVERDENTURE BARS**  
& All On 4



**CHAIR-SIDE CUSTOM STAINING**  
& Case Consulting

## In Memoriam

With great sadness we announce the passing of Life Members



### **SCHWANN, Gordon William, BA, B.Ed, DDS** **January 19, 1926 - August 11, 2013**



*Dr. Gordon Schwann passed away peacefully, age 87, in the presence of his family on August 11, 2013. Left to cherish his memory are his wife of 60 years, Kathleen "Kay"; his children, Greg (Evelyn), Lian, Joe (Sandy) and Monica; his grandchildren, Marc (Dorian), Adam and Meghan Reeson and Michela, Kiersten, Keeley and Jordon Schwann.*

*Gordon was survived by his sister Vivian and predeceased by his parents, Joe and Peggy; brothers, Joe and Paul; and sister Evelyn. Gordon was born in Regina, SK on January 19, 1926.*

*He attended St. Joseph School and Central Collegiate. His schooling was interrupted by service in the Royal Navy Fleet Air Armed Forces (1944-45) where he served as a pilot in training in England and later served as an officer in the Canadian Forces Reserve. After the war, Gordon completed his Bachelor of Arts Degree at the University of Saskatchewan. He continued his education at the University of Alberta, earning a Bachelor of Education and a Doctorate in Dental Surgery (Class of 1955). He established his dental practice in Regina and over the next 38 years enjoyed his practice, his patients and colleagues alike. He belonged to many professional associations at both the national and international level. For his commitment to dental excellence, he was made a Fellow of the International College of Dentistry.*

*To leave an online message of condolence, please visit [www.speersfuneralchapel.com](http://www.speersfuneralchapel.com)*

### **Dr. Graham Robert Matheson** **June 16, 1954 - March 23, 2014**



*On Sunday, March 23, 2014 the world became a little less bright with the passing of Dr. Graham Robert Matheson. After a brave battle, Graham peacefully surrendered to the symptomamyotrophic lateral sclerosis (ALS) surrounded by the loving women he helped to make stronger during his life: Cherie, his devoted wife and partner of 41 years;*

*Kiara, Elyra, Tabree and Volante, his adoring daughters; and Diana and Elizabeth, his younger sisters. Graham also had the privilege of welcoming two son-in-laws into the Matheson clan, Paul and Matt. With much pride, Graham doted on his four beautiful grandchildren; Chelsea, Landon, Lachlan, and Boedy, and was looking forward to being Papa to a new grand-baby in April. Growing up in the Winnipeg cold, Graham always spoke facetiously about his chilly circumstances: walking to school in snow up to his neck, sharing one boot with his sister, and walking uphill both ways to and from school. Graham's humour carried with him into the University of Manitoba, where he met Cherie. After the careful bartering of his 'perfect Chemistry notes' for a date, Graham happily began his lifelong romance with his future wife. Before long, he and Cherie moved to the west coast and their family grew to include four daughters. When asked if he'd ever wished for a son, Graham would respond no, for it was his wish to be surrounded by*

*beautiful women when he died. When he wasn't with his family, Graham was busy practicing Prosthodontics, running a well-respected practice, which he then expanded by mentoring Study Clubs composed of colleagues who quickly became friends. In his practice Graham sought to provide a gracious and comforting atmosphere, which was reflected by the pleasant demeanor of his staff, and exemplified by the finesse of his craft. Patients frequently chuckled at his endearing habit of humming away while he worked. Unfortunately, he was forced to give up this well-cultivated practice upon his diagnosis of ALS, placing his trust with someone who promised to honour Graham's legacy. Reflecting upon his life, Graham took great comfort in the fact he did not have a Bucket List, as he had lived his life actively and passionately pursuing all his dreams and therefore only wanting the closeness and comfort of his loving family in his final months. The family wishes to celebrate Graham's life privately, in a ceremony that will include only immediate family. In lieu of flowers, donations can be made in Graham's memory to the A.L.S. Society of B. C. (1-800-708-3228).*

*In no way will Graham be forgotten, for his impact upon those he loved will live on forever. Graham loved well and was well loved. He will be missed on every day that the days go on.*

### **Dr. Norman Ferguson** **May 28, 1922 - March 17, 2014**



*FERGUSON, Dr. Norman C. Norman passed away peacefully at Royal City Manor on March 17, 2014. Born May 28, 1922 in New Westminster, Norman grew up in the city and attended UBC for his pre-dental course and the North Pacific Dental College where he obtained his Doctor of Dentistry (D.M.D.). He practiced in New Westminster until age 80. Norm was*

*an honorary Fellow of the College of Dentists of Canada, a Fellow of the American College of Dentists, a Fellow of the International College of Dentists, Fellow in the Academy of Dentistry International and a member of O.K.U, International Honour Dental Fraternity. In addition to his private practice, Norm became a faculty member at UBC's Faculty of Dentistry in 1966 and continued to teach until 2005. Norman is predeceased by his sister, Frances Love and his brothers, Jack Ferguson and James Black. He leaves his wife Frances, daughter Jane Christopherson, son Jim (Sue), grandchildren Jamie (Anna) Christopherson, Ron Christopherson, Jaime Ferguson (Khalil Bhimji) and Kyle Ferguson (Sheena Urquhart) along with his great-grandchildren, Melina Christopherson, Sophia Christopherson, and Syllas Bhimji. Norman will be greatly missed by his family and many friends, including colleagues and former patients. A reception in Norman's honour will be held at a date and location to be announced later. The family wishes to especially thank the staff at Thornbridge Gardens and Royal City Manor for their wonderful and thoughtful care. In lieu of flowers the family would appreciate donations to the UBC Faculty of Dentistry - Hamber Foundation Visiting Professorship in Dental Geriatric or your favourite charity in Norman's name. - See more at:*

*<http://www.legacy.com/obituaries/vancouver/obituary.aspx?n=norman-ferguson&pid=170415592#sthash.lgJvQLpQ.dpuf>*



**CARDP**  
**ACDRP**

**Congrès annuel 2014**  
**18 au 20 Septembre, Montréal, QC**

**Le Westin**

**PROGRAMME SCIENTIFIQUE - SCIENTIFIC PROGRAM**

*ATTEINDRE LA DENTISTERIE DU FUTUR - TOMORROW'S DENTISTRY TODAY*

## **Cours pratiques pré-congrès – Pre-Meeting Hands-on Courses**

- La fine pointe de l'Endodontie / Forward Endodontics: Dr. Stewart Shapiro
- La versatilité du Waterlase / Versatility of Waterlase: Dr. Howard Golan

## **Conférences d'une heure - One hour presentations**

Traduction simultanée – Simultaneous Translation

Dr. Robert Vogel Milton, Florida	- Fusion de l'art, de la science et de la technologie en Dentisterie implantaire - Blending of Art, Science and Technology in Implant Dentistry
Dr. Gilles Lavigne Montréal, Qc	- L'apnée du sommeil, le bruxisme et les douleurs faciales - Sleep Apnea, Bruxism and Facial Pain
Dr. Izchak Barzilay Toronto, ON	- Dentisterie de reconstruction numérique - Digital Reconstructive Dentistry
Mr. Hiam Keren, CDT Montréal, Qc	- Planification des traitements et fabrication de prothèses à l'aide de prototypes numériques - Treatment Planning and Prosthesis Fabrication Using Digital Technology Prototypes
Dr Pierre Boudrias Montréal, Qc	- Managing the esthetic zone in Implantology - La gestion de la zone esthétique en Implantologie
Dr Yvan Fortin Montréal - Québec	- Restauration du maxillaire édenté: choix des options prothétiques - Restoration of the Edentulous Maxilla: Choosing Prosthetic Options
Dr. Mamaly Reshad Montréal, Qc	- Résection versus augmentation: prothèses implanto-portées esthétiques au maxillaire - Resection Versus Augmentation: Esthetic implant Supported Maxillary Prosthesis

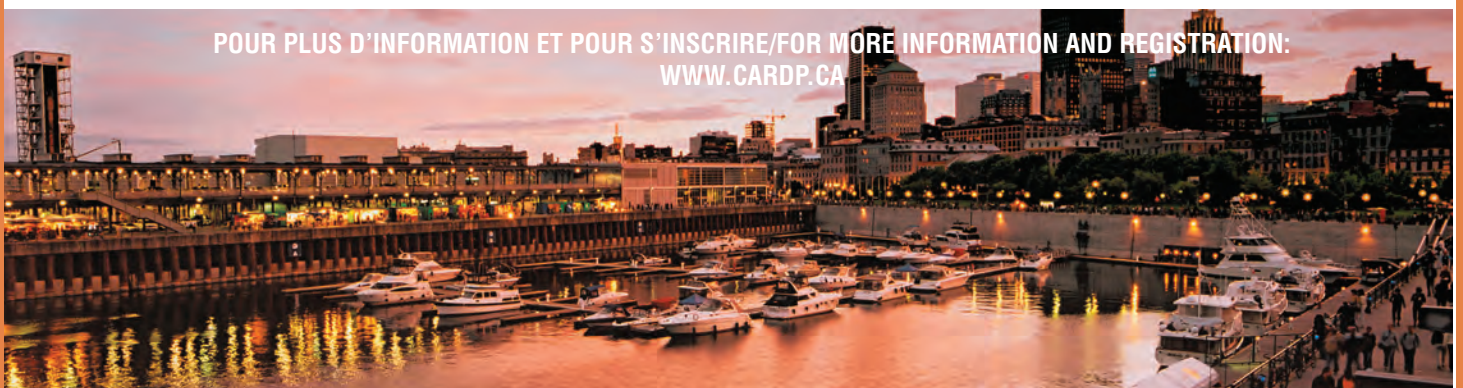## **PRÉSENTATIONS ABRÉGÉES - SHORT FORMAT LECTURES (20 minutes)**

Traduction simultanée – Simultaneous Translation

Dr. Dennis Nimchuk Vancouver, BC	- La précision avec les céramiques: le nouveau paradigme - Precision with Ceramics: the New Paradigm
Mr. Michael Schreck CDT Montréal, Qc	- Mythes et réalités des matériaux tout céramiques modernes - Myths and Reality of Modern All Ceramic Materials
Dr. Stewart Shapiro Montréal, Qc	- L'endodontie versus les implants: revue des critères de succès en endodontie - Endo versus Implants: Revisiting the Criteria for Success with Endodontics
LCol Michael Kaiser BFC/CFB Valcartier, Qc	- Le corps dentaire militaire: comment les dentistes militaires vous servent au pays et à l'étranger - The Military Dental Corps: How Our Military Dentists Serve You at Home and Abroad
Dr. Marc Shenouda Montréal, Qc	- La venue de l'imagerie 3D en dentisterie et l'utilisation de la planification numérique des implants - The Advent of 3D Imaging in Dentistry and the Use of Computer Assisted Implant Planning
Dr Louis Drouin Pointe-Claire, Qc	- Restaurer un nouvel attachement avec succès - Success in Restoring a New Attachment
Dr Alexandre Taché Montréal, Qc	- Sauver les dents à risques parodontaux utilisant le laser pour créer un nouvel attachement - Saving Periodontally Risky Teeth with the Laser Assisted New Attachment Procedure (LANAP)
Dr. Marc Spatzner, Montréal, Qc	- Can implants go bad? Prevention: better than a cure! - Les implants peuvent-ils se détériorer? Mieux vaut prévenir que guérir
Dr Pierre Boudrias Montréal, Qc	- Managing the esthetic zone in Implantology - La gestion de la zone esthétique en Implantologie

## **DÉMONSTRATIONS CLINIQUES – TABLE CLINICS**

**POUR PLUS D'INFORMATION ET POUR S'INSCRIRE/FOR MORE INFORMATION AND REGISTRATION:**  
**WWW.CARDP.CA**





**CARDP**  
**ACDRP**

**Congrès annuel 2014**  
**18 au 20 Septembre, Montréal, QC**



Dr. Izchak Barzilay  
Toronto, ON



Dr. Pierre Boudrias  
Montréal, Qc



Dr Louis Drouin  
Pointe-Claire, Qc



Dr. Yvan Fortin  
Montréal - Québec



Dr. Howard Golan  
New York, NY



LCol Michael Kaiser  
BFC/CFB Valcartier, Qc



Mr. Haim Keren  
Montréal, Qc




Dr. Gilles Lavigne  
Montréal, Qc



Dr. Dennis Nimchuk  
Vancouver, BC



Dr. Mamaly Reshad  
Montréal, Qc



Dr. Marc Shenouda  
Montréal, Qc



Mr. Michael Schreck CDT,  
Montréal, Qc



Dr. Stewart Shapiro  
Montréal, Qc



Dr. Marc Spatzner  
Montréal, Qc



Dr. Alexandre Taché  
Montréal, Qc



Dr. Robert Vogel  
Milton, Florida

## Call for Papers

CARDP's Executive Board has concluded a publishing agreement with Palmeri Publishing Inc. The Academy's Journal (CJRDP/JCDRP) is published four times a year since 2008 with a circulation of 7,000. The 2014 Journal Production Schedule is accessible at:

<http://cardp.ca/sitedocs/Ad-and-Article-submission-deadlines.pdf>

**Scientific articles are Peer Reviewed.** The Journal welcomes article contributions from its members, guest dentists and dental technologists as well as the dental Industry.

**Editor-in-chief:** Dr. Hubert Gaucher

**Associate Editors:** Drs. Maureen Andrea, Emo Rajczak and Dennis Nimchuk

**Section Editors:** Drs. Kim Parlett, Ian Tester, Ron Zokol, Yvan Fortin, Paresh Shah, Izchak Barzilay, Peter Walford, Allan Coopersmith and Mr. Paul Rotsaert

**Academic Liaison:** Dr. Peter Taylor

**I – Scientific Articles:** (Original Research Studies, Reviews, Case Reports): Please refer to these "Instructions to Authors" for details.

[http://cardp.ca/sitedocs/CARDP\\_Authors-guidlines.pdf](http://cardp.ca/sitedocs/CARDP_Authors-guidlines.pdf)

For Case Reports please review this information:

<http://cardp.ca/sitedocs/CJRDP-Case-Report-Authors.pdf>

**II – Member News:** Please forward any news of interest to the Profession.

**III – Young Authors Awards Fund:** Financial contributions to this fund will recognize a dentist with 5 years' experience or less or a graduate student in Canada, with a \$1,000 award for the best published article of the year.

**IV – Dental Student Award Fund:** Financial contributions to this fund will recognize a dental student in Canada, who will receive a \$500 award for the best published article of the year.

**V – Industry News and Product Profile Articles:** New dental products, technologies and Industry services are presented to readers using articles that originate from the Industry and that are identified as such. This information is contained in the above "Instructions to Authors" and in the following Journal Media Kit: <http://cardp.ca/sitedocs/MediaKit-2014-email.pdf>

If you have comments or suggestions about submissions or would like to become more involved with the Journal, please contact the Editor-in-Chief:

Dr Hubert Gaucher  
hgaucher@sympatico.ca  
Tel: (418) 658-9210  
Fax: (418) 658-5393



## Demande de communications

L'ACDRP a conclu une entente de publication avec Palmeri Publishing Inc. Le journal de l'Académie (CJRDP/JCDRP) est publié depuis 2008 et a une circulation de 7 000 exemplaires. Il y a quatre parutions par année. La cédule de production 2014 du Journal est accessible à:

<http://cardp.ca/sitedocs/Ad-and-Article-submission-deadlines.pdf>

**Les articles scientifiques font l'objet d'une revue par des pairs.** Le Journal accueille des articles de ses membres, de dentistes et de prothésistes dentaires invités ainsi que de l'Industrie dentaire.

**Rédacteur en chef:** Dr Hubert Gaucher

**Rédacteurs associés:** Drs Maureen Andrea, Emo Rajczak et Dennis Nimchuk

**Rédacteurs de sections:** Drs Kim Parlett, Ron Zokol, Yvan Fortin, Paresh Shah, Izchak Barzilay, Peter Walford, Allan Coopersmith et M. Paul Rotsaert

**Liaison académique:** Dr. Peter Taylor

**I – Articles scientifiques:** (Recherches originales, revues, rapports de cas): Veuillez vous référer aux «Instructions aux auteurs» pour les détails.

[http://cardp.ca/sitedocs/CARDP\\_Authors-guidlines.pdf](http://cardp.ca/sitedocs/CARDP_Authors-guidlines.pdf)

Pour le Rapport de cas, veuillez consulter le document suivant:

<http://cardp.ca/sitedocs/CJRDP-Case-Report-Authors.pdf>

**II – Nouvelles des membres:** S.V.P nous envoyer toute information pertinente à la profession.

**III – Bourse pour les jeunes auteurs:** Les contributions financières permettront de remettre une bourse de 1 000\$ à un dentiste ayant moins de cinq ans de pratique et/ou à un(e) étudiant(e) diplômé(e) au Canada pour le meilleur article publié au cours de l'année.

**IV – Bourses pour étudiant(e) en Médecine dentaire:** Les contributions financières permettront de remettre une bourse de 500\$ à un étudiant ou étudiante en Médecine dentaire au Canada pour le meilleur article publié au cours de l'année.

**V – Nouvelles de l'Industrie et Articles publicitaires:** Les nouveaux produits, technologies et services de l'Industrie sont présentés aux lecteurs utilisant des articles venant de l'Industrie et qui sont identifiés comme tels. Cette information est contenue dans les «Instructions aux auteurs» ci-haut ainsi que dans la Trousse Média: <http://cardp.ca/sitedocs/MediaKit-2014-email.pdf>

Si vous avez des commentaires ou des suggestions ou si vous désirez vous impliquer davantage dans notre Journal, veuillez communiquer avec le Rédacteur en chef:

Dr Hubert Gaucher  
hgaucher@sympatico.ca  
tél: (418) 658-9210  
télécopieur: (418) 658-5393



**Where Dentistry Becomes Art**

**The Imprint of Beauty is our Commitment to Excellence**

**Specializing In Implants**

- BICON • BIOMET 3I • BIOHORIZONS • DENTSPLY IMPLANTS • MIS
- NOBEL BIO CARE • STRAUMANN • SOUTHERN IMPLANTS • THOMMEN • ZIMMER

**Other Specialities**

Captex System

IPS e.max

Gradia Composite System

CAD/CAM System inEos Blue

Implants

Laser Welding Technology

TCS Flexible Denture

SR Ivocap Injection System

**Picasso Dental Studios Inc.**  
[www.picassodentalstudios.com](http://www.picassodentalstudios.com)

Masoud Niknejad, RDT  
565 Edward Ave, Unit 4 Richmond Hill, On L4C 9W8  
Tel: 905.883.9447

**ASTRA TECH  
IMPLANT SYSTEM**



# Join the **EV**olution

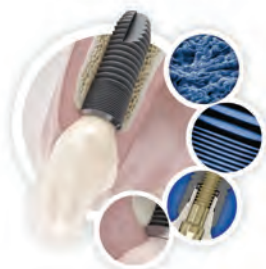

The new  
**ASTRA TECH Implant System™ EV**  
– now available

Learn more



[www.jointheev.com](http://www.jointheev.com)



The foundation of this evolutionary step remains the unique **ASTRA TECH Implant System BioManagement Complex**, well-documented for its long-term marginal bone maintenance and esthetic results. [www.dentsplyimplants.com](http://www.dentsplyimplants.com)

**DENSPLY  
IMPLANTS**